

Giant Benign Serous Cystadenoma with Unusual Dermatologic Manifestations Despite a Normal Menstrual Pattern: A Case Report and Review of Diagnostic Challenges

ARTICLE INFO


DOI: 1052547/sjrm.11.1.7

ABSTRACT

Article Type

Case Report

Authors

Mohammad Reza Nateghi^{1,2} ,
Bahareh Khandzad¹

1- Sarem Gynecology, Obstetrics and Infertility Research Center, Sarem Women's Hospital, Iran University of Medical Science (IUMS), Tehran, Iran.

2- Sarem Cell Research Center (SCRC), Sarem Women's Hospital, Tehran, Iran. Payame Noor University, Tehran, Iran.

*Corresponding Authors:

Mohammad Reza Nateghi; Sarem Gynecology, Obstetrics and Infertility Research Center, Sarem Women's Hospital, Iran University of Medical Sciences, Tehran, Iran.

Address: Sarem Women Hospital, Basij Square, Phase 3, Ekbatan Town, Tehran, Iran. Postal code: 1396956111, Phone: +98 (21) 44670888, Fax: +98 (21) 44670432.

Received: 29 May 2026

Accepted: 19 June 2026

e Published: 23 June 2026

Article History

Introduction: Serous ovarian cysts are among the most common benign epithelial ovarian tumors. Although these lesions are typically diagnosed at an early stage before reaching a considerable size, delayed diagnosis may occur in some cases due to the absence of specific symptoms or the presence of unusual clinical manifestations. Reporting cases with exceptionally large tumors and non-gynecological presentations may enhance physicians' awareness and facilitate earlier diagnosis of such lesions.

Case Presentation: A 38-year-old woman had been repeatedly evaluated by a dermatologist because of persistent skin and hair problems. Despite these complaints, she reported a normal menstrual pattern. Further investigations, including pelvic ultrasonography, revealed a large cystic mass in the left adnexa. Magnetic resonance imaging (MRI) demonstrated a unilocular, thin-walled abdominopelvic cystic lesion measuring 260 × 215 × 150 mm in the left adnexal region, without solid components or papillary projections. The patient underwent laparoscopic surgery on May 7, 2024. Initially, approximately 2500 mL of cystic fluid was aspirated under ultrasound guidance and sent for cytological evaluation. Subsequently, laparoscopic cystectomy with complete excision of the cyst wall was performed. Histopathological examination confirmed the diagnosis of a benign serous cystadenoma. Follow-up ultrasonography after surgery revealed no abnormal findings.

Conclusion: Giant ovarian cysts may present with unusual manifestations despite a normal menstrual pattern and the absence of prominent gynecological symptoms. This case highlights the importance of comprehensive evaluation in patients with nonspecific complaints and demonstrates that selected cases of large ovarian cysts can be successfully managed using a laparoscopic approach.

Keywords: Benign Serous Cystadenoma; Giant Ovarian Cyst; Left Adnexa; Laparoscopy; Cystectomy; Case Report

Introduction

Ovarian cysts are among the most common adnexal masses encountered in women and encompass a broad spectrum of functional, benign, and malignant lesions. With the widespread use of imaging modalities, particularly ultrasonography and magnetic resonance imaging (MRI), the detection of these lesions at earlier stages has significantly increased [1,2]. Nevertheless, some ovarian cysts may remain undiagnosed for prolonged periods because of their slow growth, benign nature, and lack of specific symptoms, eventually reaching considerable dimensions. Such lesions, commonly referred to as giant ovarian cysts in the literature, have become less frequent in recent decades, as most adnexal masses are identified and treated before attaining such large sizes [3,4].

Serous cystadenoma is one of the most common benign epithelial tumors of the ovary and is typically observed in women of reproductive age and in the premenopausal period. These tumors generally present as unilocular or multilocular thin-walled cystic lesions and remain asymptomatic in many cases [5,6]. As their size increases, patients may develop symptoms such as abdominal fullness, progressive abdominal distension, pelvic pain, pressure effects on the gastrointestinal or urinary tract, and occasionally menstrual irregularities. However, the relationship between tumor size and symptom severity is not always linear, and some patients with remarkably large masses may experience only mild or nonspecific manifestations [7,8].

One of the major challenges in the management of large adnexal masses is distinguishing benign from malignant lesions. Careful assessment of imaging characteristics, including wall thickness, the presence of solid components, papillary projections, complex septations, and associated clinical and laboratory findings, plays a crucial role in determining the most appropriate therapeutic approach. In recent years, advances in minimally invasive surgical techniques have enabled the successful laparoscopic management of selected giant ovarian cysts while preserving ovarian function. Compared with conventional open surgery, this approach offers several advantages, including reduced postoperative pain, shorter hospital stay, faster recovery, and improved cosmetic outcomes [9-11].

An important consideration is that some patients with large ovarian cysts may lack classic gynecological symptoms and instead present with complaints that do not initially appear to be related to the reproductive system. In such circumstances, diagnosis may be delayed, highlighting the importance of comprehensive clinical evaluation and careful attention to nonspecific findings. Reporting these uncommon presentations may increase physicians' awareness of the diverse clinical manifestations of

ovarian masses and reduce the likelihood of overlooking such lesions [12,13].

The incidence of giant ovarian cysts has declined in recent years due to improved access to diagnostic imaging and earlier detection of adnexal pathology. However, delayed diagnosis may still occur in patients with atypical clinical manifestations or the absence of characteristic symptoms, allowing these lesions to attain substantial dimensions. Furthermore, determining the optimal management strategy for giant ovarian cysts remains a clinical challenge. The present report describes a rare case of a giant benign serous cystadenoma of the left ovary in a 38-year-old woman who, despite having a normal menstrual pattern, underwent evaluation for non-gynecological complaints, namely skin and hair problems, leading to the incidental discovery of a large adnexal mass. This report emphasizes the importance of considering adnexal pathology in patients presenting with nonspecific symptoms and highlights the valuable role of imaging modalities in achieving timely diagnosis. The unusual clinical presentation, remarkable size of the lesion, benign histopathological findings, and successful laparoscopic management make this case noteworthy and may provide useful insights for gynecologists and minimally invasive surgeons involved in the diagnosis and treatment of similar cases.

Case Presentation

A 38-year-old woman had been referred to a dermatologist on several occasions because of persistent skin and hair problems. Despite repeated evaluations and specialist consultations, no definitive cause for her complaints had been identified. An important finding in her medical history was that, despite these symptoms, she reported a completely normal menstrual pattern and had no history of menstrual irregularities, amenorrhea, menorrhagia, or other cycle-related disorders. Due to the persistence of her symptoms and the need for further investigation, evaluation of the reproductive system, including pelvic ultrasonography, was requested.

The patient was subsequently referred to Sarem Super Specialty Hospital for further assessment. Initial transvaginal ultrasonography revealed a very large cystic mass arising from the left ovary. The lesion measured approximately 220×210×105 mm and contained anechoic fluid. No solid component, complex septation, or other sonographic features suggestive of malignancy were identified. The estimated cyst volume was approximately 2500 mL. Following these findings, an abdominal ultrasound was performed on April 22, 2024, which demonstrated a large cystic mass extending from the pelvis to the epigastric region. The lesion measured approximately 380×105×230 mm, indicating extensive involvement of the abdominal cavity. Given the considerable size of the mass and the need for further characterization,

magnetic resonance imaging (MRI) was requested (Figure 1).

MRI performed on May 25, 2024, confirmed the presence of a solitary unilocular abdominopelvic cystic lesion arising from the left adnexa. The lesion measured 260×215×150 mm and demonstrated a thin wall without papillary projections, mural nodules, solid components, or any other radiological features suggestive of malignancy. Overall, the imaging findings were highly suggestive of a benign cystic lesion of left adnexal origin. Considering the giant size of the mass, the potential risk of pressure-related complications, and the need for definitive diagnosis, surgical intervention was planned.

After completion of preoperative evaluations and obtaining informed consent, the patient underwent laparoscopic surgery at Sarem Super Specialty Hospital on May 7, 2024. The procedure was performed under general anesthesia. Following sterile preparation and draping, an initial ultrasound-guided assessment confirmed the presence of a giant ovarian cyst extending up to the epigastric region. To facilitate minimally invasive surgery and minimize the risk of uncontrolled cyst rupture, an umbilical trocar was inserted before establishment of pneumoperitoneum.

A sample of the cystic fluid was aspirated into a heparinized syringe and sent for cytological analysis. Subsequently, the cyst was completely decompressed, yielding approximately 2500 mL of fluid. Following drainage, a Veress needle was inserted, carbon dioxide pneumoperitoneum was established, and the primary and accessory laparoscopic trocars were placed. Peritoneal washing was obtained and sent for cytological examination.

Intraoperative exploration revealed adhesions between the bowel and ovary as well as between the fallopian tube and ovary. These adhesions were carefully released under direct visualization. Following adhesiolysis, the cyst wall was completely dissected from the ovarian tissue and excised. Hemostasis of the ovarian bed was achieved using suturing techniques. The abdominal cavity was then thoroughly irrigated and suctioned. After confirmation of adequate hemostasis and absence of active bleeding, all trocars were removed under direct vision.

The excised cyst wall was submitted for histopathological evaluation. Pathological examination confirmed the diagnosis of a benign ovarian serous cystadenoma. Cytological analysis of both the cyst fluid and peritoneal washing specimens showed no evidence of malignancy. The postoperative course was uneventful, and the patient was discharged in good general condition. During follow-up, she remained clinically well and reported no complaints. Follow-up ultrasonography performed on August 26, 2024, demonstrated no residual lesion or abnormal findings within the pelvis or adnexal regions, indicating a satisfactory treatment outcome.

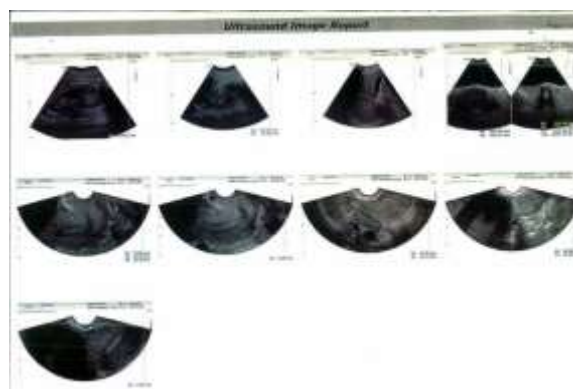

Figure 1: Ultrasound Image Report of Giant Benign Serous Adenoma Cyst of the Left Ovarian with Unusual Clinical Manifestations.

Discussion

Serous cystadenomas are among the most common benign epithelial ovarian tumors and account for a substantial proportion of benign adnexal masses [14,15]. These tumors typically present as thin-walled cystic lesions containing clear serous fluid and are most frequently encountered in women of reproductive age and in the premenopausal period [16]. Although the majority are diagnosed when they are still small or moderate in size, some lesions may remain undetected for extended periods because of their slow growth, benign biological behavior, and lack of specific symptoms. As a result, they may eventually reach giant dimensions. Despite a decline in the incidence of giant ovarian cysts due to widespread access to imaging modalities, these cases continue to pose important diagnostic and therapeutic challenges [17,18]. Reporting such cases is valuable not only because of the remarkable size of the lesions but also because of their diverse clinical manifestations, diagnostic complexity, the need to distinguish them from malignant tumors, and the selection of the most appropriate treatment strategy. Furthermore, publication of these cases may increase physician awareness regarding large adnexal masses and support the expanding role of minimally invasive surgical approaches.

The present report describes a 38-year-old woman who was evaluated and treated at Sarem Super Specialty Hospital. Unlike many previously reported cases, the patient was primarily investigated for skin and hair problems and did not exhibit any significant menstrual abnormalities. Imaging studies revealed a giant left adnexal cyst with an estimated volume of approximately 2500 mL, without solid components or radiological features suggestive of malignancy. The patient underwent successful laparoscopic cystectomy, and histopathological examination confirmed the diagnosis of a benign serous cystadenoma. The most notable aspects of this case

were the considerable size of the lesion, the absence of prominent gynecological symptoms, its detection during evaluation of non-gynecological complaints, and the successful management through a minimally invasive laparoscopic approach.

Mpourazanis et al. reported a giant benign ovarian serous cystadenoma in an 80-year-old postmenopausal woman who presented with abdominal pain and dyspnea and underwent total hysterectomy with bilateral salpingo-oophorectomy [19].

Histopathological examination confirmed the benign nature of the lesion. Similar to our case, the final diagnosis was benign serous cystadenoma and the postoperative outcome was favorable. However, our patient was of reproductive age and was diagnosed during evaluation of skin and hair complaints rather than pressure-related symptoms. In addition, ovarian preservation through laparoscopic cystectomy was possible in our patient, whereas radical surgery was performed in the reported postmenopausal patient.

Kelly et al. described a giant benign ovarian serous cystadenoma in a patient with a body mass index of 45 that was discovered incidentally during elective bariatric surgery [20]. The patient was completely asymptomatic, and pathology confirmed a benign serous cystadenoma following laparotomy, oophorectomy, and cystectomy. Similar to our findings, the lesion was benign and had reached a considerable size. However, while the tumor in their report was detected incidentally in an asymptomatic patient, our patient was diagnosed during evaluation of persistent skin and hair complaints. Furthermore, our patient was successfully managed laparoscopically, whereas open surgery was selected in their case.

Agah et al. reported a giant ovarian serous cystadenoma in a young woman who had been treated for gastrointestinal complaints for several months because she lacked gynecological symptoms [21]. Ultrasonography eventually revealed a giant ovarian cyst, and surgical removal of a 40-cm, 8-kg mass confirmed the diagnosis of benign serous cystadenoma. Similar to our case, the lesion was ultimately diagnosed as a benign serous cystadenoma and was preceded by nonspecific clinical manifestations. In both cases, the absence of obvious gynecological symptoms contributed to delayed recognition of the mass. However, our patient presented with dermatologic complaints, whereas the patient described by Agah et al. initially presented with gastrointestinal symptoms. These findings underscore the fact that giant ovarian cysts may manifest through nonspecific and seemingly unrelated symptoms.

Similarly, Sujatha and Babu reported a giant ovarian serous cystadenoma in a 66-year-old postmenopausal woman who presented with progressive abdominal distension over a two-year period [22]. The cyst occupied the entire abdominal cavity, and laparotomy

resulted in removal of a 60 × 47 × 30 cm mass weighing 23 kg. Histopathological examination confirmed benign serous cystadenoma. Although the pathological diagnosis was similar to that of our patient, important differences existed. Our patient was younger, remained in the reproductive age group, and lacked severe pressure-related symptoms. Moreover, laparoscopic management was feasible in our case, whereas laparotomy was required in the previously reported patient because of the extraordinary size of the lesion. These differences may be attributable to variations in tumor size, patient characteristics, and the feasibility of minimally invasive surgery in individual cases.

Conclusion

Although giant benign ovarian serous cystadenomas have become less common in the era of advanced imaging techniques, they may still present with atypical clinical manifestations and without classic gynecological symptoms. The present case demonstrates that even in the presence of a large adnexal mass, menstrual function may remain completely normal, and the patient may initially seek medical attention for non-gynecological complaints such as skin and hair problems. These findings highlight the importance of comprehensive clinical assessment and maintaining a high index of suspicion for underlying pelvic pathology in patients with persistent nonspecific symptoms. Furthermore, this case illustrates that, with careful preoperative evaluation and appropriate patient selection, giant benign ovarian cysts can be successfully managed through a laparoscopic approach while preserving ovarian function. Reporting such cases may enhance clinicians' awareness of the diverse presentations of ovarian masses and support the broader application of minimally invasive surgical techniques in selected patients.

Ethical Issue

In conducting this research, all ethical principles in medical and biological research were observed in accordance with the Declaration of Helsinki, and the rights, dignity, and confidentiality of the participants were protected.

Conflict of Interests

There was no conflict of interest in this study.

Source of Funding

The costs of this project were funded by the Sarem Gynecology, Obstetrics and Infertility Research Center.

References

1. Sahu SA, Shrivastava D, A Comprehensive Review of Screening Methods for Ovarian Masses: Towards Earlier Detection. *Cureus*, 2023. 15(11): e48534.
2. Nikolić O, Manganaro L, Garcia MO, Nougaret S, Thomassin-Naggara I, Nicola R, et al., ESUR female pelvis group approach to cystic female pelvic lesions. *Insights into Imaging*, 2026. 17(1): 51.
3. Albers CE, Ranjit E, Sapra A, Bhandari P, Wasey W, Clinician Beware, Giant Ovarian Cysts are Elusive and Rare. *Cureus*, 2020. 12(1): e6753.
4. Melnyk M, Starczewski A, Nawrocka-Rutkowska J, Gorzko A, Melnyk B, Szydłowska I, Giant Ovarian Tumors in Young Women: Diagnostic and Treatment Challenges-A Report of Two Cases and Narrative Review of the Recent Literature. *J Clin Med*, 2025. 14.
5. Jayakumar J, Shanker S, T S, Kailash N, VR R, Adnexal lesions in post-menopausal women: A radiopathological correlation. *Journal of Research in Applied and Basic Medical Sciences*, 2024. 10(3): 266-278
6. Mascilini F, Moro F, Pasciuto T, Sladkevicius P, Froyman W, Jokubkiene L, et al., Imaging in gynecological disease (28): clinical and ultrasound characteristics of serous and mucinous cystadenomas in the adnexa. *Ultrasound in Obstetrics & Gynecology*, 2025. 66(2): 233-241.
7. Amara A, Adem A, Salhi H, El Magroud M, Zaari N ,Ammor A, et al., Giant serous cystadenoma in an adolescent: A case report. *SAGE Open Medical Case Reports*, 2024. 12: 2050313X241296296.
8. Katke R, Waje A, Rare presentation of serous cystadenoma as hemorrhagic cyst. *Obstet Gynecol Int J*, 2015. 2(4): 0.0045.
9. Carvalho JP, Moretti-Marques R, Filho A, Adnexal mass: diagnosis and management. *Rev Bras Ginecol Obstet*, 2020. 42(7): 438-443.
10. Nwajei A-M, Characterization of Adnexal Masses by Current Imaging Modalities. 2023.
11. D'Amario A, Ambrosini R ,Gullino A, Grazioli L, Role of Imaging Techniques in Ovarian Cancer Diagnosis: Current Approaches and Future Directions. *Cancers*, 2026. 18(1): 173.
12. Bašković M, Habek D, Zaninović L, Milas I, Pogorelić Z, The Evaluation, Diagnosis, and Management of Ovarian Cysts, Masses, and Their Complications in Fetuses, Infants, Children, and Adolescents. *Healthcare (Basel)*, 2025. 13.(7).
13. Bašković M, Habek D, Zaninović L, Milas I, Pogorelić Z, The Evaluation, Diagnosis, and Management of Ovarian Cysts, Masses, and Their Complications in Fetuses, Infants, Children, and Adolescents. *Healthcare*, 2025. 13: 775.
14. Mbabazi E, Dushimiyimana B, Ruzindana K, Musana FRM, Getaneh FB, Manirakiza F, A Synchronous Occurrence of Serous and Mucinous Cystadenomas of the Ovaries: Case Report and Review of the Literature. *International Medical Case Reports Journal*, 2026: 579699.
15. Balhara K, Mallya V, Khurana N, Tempe A, Coexisting ovarian serous cystadenoma with fibroma: A very unusual combination. *Journal of Cancer Research and Therapeutics*, 2023. 19(5): 1474-1476.
16. Ohya A, Fujinaga Y, Magnetic resonance imaging findings of cystic ovarian tumors: major differential diagnoses in five types frequently encountered in daily clinical practice. *Japanese Journal of Radiology*, 2022. 40(12): 1213-1234.
17. Ning K, Salamone A, Manos L, Lafaro KJ, Afghani E, Serous Cystadenoma: A Review on Diagnosis and Management. *J Clin Med*, 2023. 12.(23).
18. Karoumpalis I, Christodoulou DK, Cystic lesions of the pancreas. *Annals of Gastroenterology: Quarterly Publication of the Hellenic Society of Gastroenterology*, 2016. 29(2): 155.
19. Mpourazanis G, Ntanasias A, Aliri M, Melissi E, Christodoulou G, Alefragkis D, et al.,

Giant Benign Ovarian Serous Cystadenoma in a Postmenopausal Woman .Cureus, 2026. 18.(5).

20. Kelly LP, Patel RB, Laan D, Incidentally Discovered Giant Benign Ovarian Serous Cystadenoma in Elective Bariatric Surgery. Cureus, 2024. 16(5): e60807.
21. Agah J, Jafarzadeh Esfehiani R, Kamalimanesh B, Fattahi Abdizadeh M, Jalilian AR, Mismanagement of a Huge Ovarian Serous Cystadenoma in a Young Girl; a Case Report. Journal of Midwifery and Reproductive Health, 2015. 3(1): 315-317.
22. Sujatha VV, Babu SC, Giant ovarian serous cystadenoma in a postmenopausal woman: a case report. Cases J, 2009. 2: 7875.