Sarem Journal of Medical Research. Volume 10, Issue 4, Winter 2026: 191- 196

Congenital Chylothorax in an Extreme Preterm Infant

ARTICLE INFO

DOI: 1052547/sjrm.10.4.4

Article Type

Case Report

Authors

Shima Salehi[1], Zohreh Abedini[1], Hadis Mohammadian[1], Maryam Sanaye Naderi[1,2], Mohammad Reza Nateghi[1,2 *]

1- Sarem Gynecology, Obstetrics and Infertility Research Center, Sarem Women's Hospital, Iran University of Medical Science (IUMS), Tehran, Iran.
2- Sarem Cell Research Center (SCRC), Sarem Women's Hospital, Tehran, Iran.

Corresponding Authors:
Mohammad Reza Nateghi; Sarem Gynecology, Obstetrics and Infertility Research Center, Sarem Women's Hospital, Iran University of Medical Sciences, Tehran, Iran.
Address: Sarem Women Hospital, Basij Square, Phase 3, Ekbatan Town, Tehran, Iran. Postal code: 1396956111, Phone: +98 (21) 44670888, Fax: +98 (21) 44670432.

Received: 06 January 2026
Accepted: 06 February 2026
e Published: 14 February 2026

Article History

ABSTRACT

Introduction: Congenital chylothorax is a rare but clinically significant cause of pleural effusion in the neonatal period, particularly among preterm infants, in whom it may be associated with severe respiratory, metabolic, and infectious complications. This condition results from leakage of lymphatic fluid into the pleural space, and timely diagnosis and appropriate management play a crucial role in determining patient outcomes. Given its low incidence and complex clinical presentation, reporting individual cases may contribute to increased clinical awareness and improved diagnostic and therapeutic strategies.

Case Presentation: We report a case of an extreme preterm female neonate born at 27 weeks of gestation with a birth weight of 900 grams, who was admitted to the neonatal intensive care unit of Sarem Women's Hospital (Tehran, Iran) due to severe respiratory distress immediately after birth. Following initiation of enteral feeding, the infant developed worsening respiratory symptoms, and imaging studies revealed a pleural effusion. Thoracentesis yielded milky-appearing pleural fluid, and laboratory analysis demonstrated elevated triglyceride levels and lymphocytosis, confirming the diagnosis of neonatal chylothorax. Despite conservative management, including cessation of enteral feeding, total parenteral nutrition, chest tube placement, and surgical consultation, surgical intervention was not feasible due to extreme prematurity and very low birth weight. During the subsequent hospital course, the patient developed sepsis and pneumonia and ultimately succumbed to these complications.

Conclusion: Congenital chylothorax, particularly in very preterm infants, represents a significant diagnostic and therapeutic challenge and may be associated with poor outcomes. Worsening respiratory distress following the initiation of enteral feeding should raise clinical suspicion for this condition. Early diagnosis and a multidisciplinary management approach may contribute to improved clinical outcomes. This case highlights the importance of considering chylothorax as a critical differential diagnosis in preterm neonates presenting with pleural effusion.

Keywords: Congenital Chylothorax; Pneumonia; Respiratory Distress; Prematurity; Case Report.

[Downloaded from saremjrm.com on 2026-11-24]

[DOI: 10.66224/sjrm.10.4.4]

Introduction

Chylothorax is defined as the abnormal accumulation of lipid-rich lymphatic fluid within the pleural space, resulting from leakage or obstruction of the thoracic duct or other lymphatic vessels [1, 2]. Although this condition can occur in adults and older children, it is considered a rare yet potentially life-threatening disorder in the neonatal period, particularly among preterm infants [3]. Chylothorax represents the most common cause of neonatal pleural effusion; however, its incidence is estimated from 1/10,000 to 1/24,000 births, with a mortality rate ranging between 30% and 70%. The clinical significance of this condition is substantial, given its close association with respiratory failure, metabolic disturbances, malnutrition, immunodeficiency, and increased mortality in neonates, especially those with lower gestational age [4].

From an etiological perspective, neonatal chylothorax is broadly classified into congenital and acquired forms. Congenital chylothorax is typically attributed to developmental abnormalities of the lymphatic system, defects in the formation or obstruction of the thoracic duct, or elevated pressure within the fetal lymphatic circulation. This form may present as an isolated condition or in association with genetic and chromosomal abnormalities such as Turner syndrome, Down syndrome, and congenital heart defects [5, 6]. In contrast, acquired chylothorax most commonly arises secondary to thoracic surgical procedures, trauma, infections, central venous thrombosis, or the use of central venous catheters, particularly in neonates admitted to neonatal intensive care units [7, 8]. From a pathophysiological standpoint, leakage of chylous fluid into the pleural space leads to the accumulation of a significant volume of effusion, resulting in compression of the lung parenchyma, reduced ventilatory capacity, and the development or exacerbation of respiratory distress. Beyond its mechanical effects on pulmonary function, the continuous loss of chyle, which contains substantial amounts of proteins, electrolytes, triglycerides, fat-soluble vitamins, and lymphocytes, can result in hypoproteinemia, electrolyte imbalances, severe malnutrition, and immunodeficiency. Consequently, affected neonates become highly susceptible to opportunistic infections, sepsis, and adverse short- and long-term outcomes [9, 10]. The clinical manifestations of neonatal chylothorax are variable and depend on the volume of accumulated fluid, the rate of chyle leakage, and the infant's underlying clinical condition [11].

The most common presentations include respiratory distress, tachypnea, oxygen desaturation, and the need for advanced respiratory support. In many cases, symptoms worsen with the initiation or escalation of enteral feeding, a feature that may serve as an important diagnostic clue. The diagnosis of chylothorax is based on a combination of clinical findings, chest imaging, and pleural fluid analysis. The presence of milky-appearing pleural fluid, elevated triglyceride levels (typically >110 mg/dL), and lymphocyte predominance on cellular analysis are considered key diagnostic criteria [12, 13]. Management of neonatal chylothorax is often challenging and requires a multidisciplinary approach involving neonatologists, pediatric surgeons, and nutrition specialists. Initial treatment is generally conservative and includes pleural drainage, cessation of enteral feeding, initiation of total parenteral nutrition, and, in selected cases, the use of diets enriched with medium-chain triglycerides. In cases refractory to conservative management, pharmacological agents such as octreotide and, ultimately, surgical interventions may be considered. However, in extremely preterm and very-low-birth-weight infants, therapeutic options are considerably limited, and the risk of complications and mortality is markedly increased [14, 15].

Despite significant advances in neonatal intensive care, chylothorax remains associated with a high rate of morbidity and mortality, particularly among extremely preterm, very-low-birth-weight infants. Reporting rare and complex cases can play a crucial role in enhancing clinical awareness, improving early diagnosis, and guiding optimal therapeutic strategies. Therefore, the present article describes and analyzes a case of neonatal chylothorax in an extremely preterm infant, characterized by severe respiratory distress and a complicated clinical course that ultimately resulted in an unfavorable outcome. This case report aims to contribute to a better understanding of the diagnostic and therapeutic challenges associated with this rare condition in the extremely preterm neonatal population.

Case Presentation

The patient was a preterm female neonate born in Sarem Women's Hospital at 27 weeks of gestation with a birth weight of 900 g, length of 36 cm, head circumference of 32.5 cm, and chest circumference of 20 cm. At birth, the heart rate was 165 beats per minute, and the respiratory rate was 71 breaths per minute. She was delivered by cesarean section with an initial diagnosis of prematurity and respiratory distress. Apgar scores were 6 and 7 at the first and fifth minutes, respectively.

Due to ineffective spontaneous respiration at birth, the neonate was immediately intubated and transferred to the neonatal intensive care unit (NICU). The initial diagnoses at admission were extreme prematurity and respiratory distress. Maternal obstetric history was notable for gestational diabetes mellitus treated with insulin, vaginal bleeding, and abdominal pain at 23 weeks of gestation, and prolonged rupture of membranes for approximately 48 hours before delivery. Following admission, the neonate received surfactant therapy and was supported with synchronized intermittent mandatory ventilation

[Downloaded from saremjrm.com on 2026-11-24]

[DOI: 10.66224/sjm.10.4.4]

(SIMV). Despite repeated attempts, successful weaning from mechanical ventilation was not achieved during the first two weeks of life, and on day 17 of hospitalization, respiratory support was transitioned to nasal continuous positive airway pressure (nCPAP).

With the initiation of enteral feeding and gradual advancement of milk volume to 15 mL, the infant developed oxygen desaturation and worsening respiratory distress. Chest imaging and thoracic ultrasonography revealed the presence of pleural effusion. At the initial stage, thoracentesis was performed, and approximately 7 mL of milky-appearing fluid was drained, resulting in a temporary improvement in respiratory status. In response to these findings, enteral feeding was discontinued, and given the suspected role of the peripherally inserted central catheter (PICC) in the development of the condition, the catheter was removed. The infant was subsequently placed on total parenteral nutrition (TPN).

Upon reinitiation of enteral feeding and advancement again to a similar volume, respiratory symptoms recurred, and reaccumulation of pleural fluid was confirmed (Figure 1). At this stage, with a strong clinical suspicion of chylothorax, a chest tube was inserted. Laboratory analysis of the pleural fluid, including elevated triglyceride levels and lymphocyte predominance, confirmed the diagnosis of neonatal chylothorax. Based on the surgical team's recommendation, a conservative management strategy was adopted, consisting of prolonged cessation of enteral feeding and continuation of TPN to allow for potential spontaneous closure of the lymphatic leak.

Due to the need for highly specialized care and the limitations of available therapeutic options, the neonate was referred to a tertiary neonatal and pediatric center. However, owing to the extremely low birth weight, surgical intervention was not feasible, and medical management was continued. Unfortunately, during the subsequent hospital course, the patient developed sepsis and pneumonia and, despite comprehensive therapeutic measures, died after two weeks of hospitalization at the referral center.

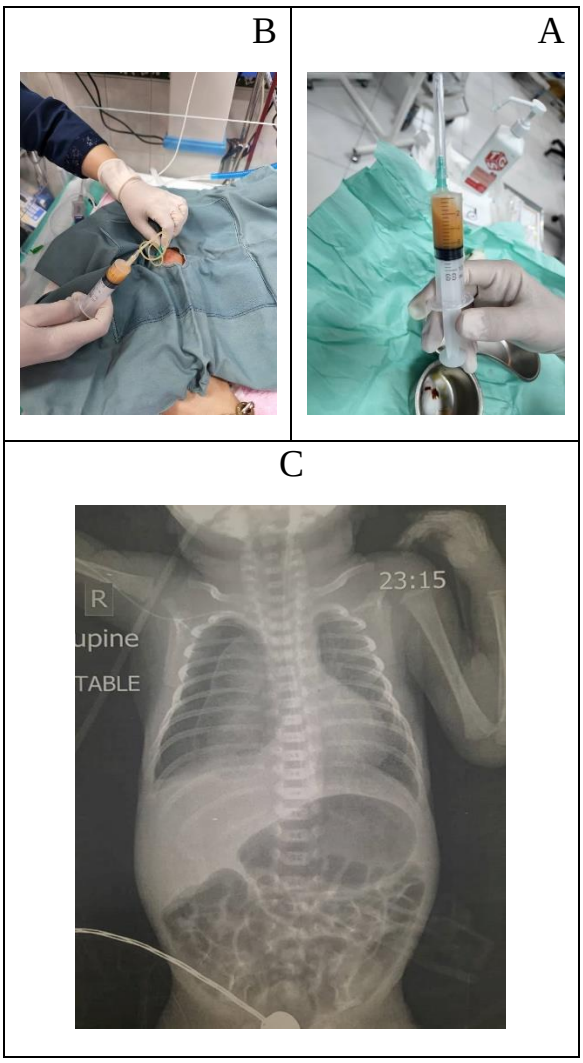

Figure 1. A) Macroscopic appearance of the pleural fluid drained from the neonatal pleural space and collected in a syringe. The fluid shows a turbid, milky appearance, which is considered a classic finding of chylothorax. This gross appearance, together with the clinical and imaging findings, strengthens the clinical suspicion of lymphatic leakage and necessitates further laboratory evaluation to confirm the diagnosis of chylothorax. **B)** Clinical view of pleural fluid drainage via a chest tube in a neonate admitted to the neonatal intensive care unit. The outflow of milky fluid through the chest drain provides direct evidence of neonatal chylothorax and illustrates the role of controlled invasive interventions in improving respiratory distress and reducing pressure on the lung parenchyma. This image highlights the importance of timely diagnosis and appropriate management of pleural effusion in extremely preterm infants. **C)** Pleural effusion.

[Downloaded from saremjrm.com on 2026-11-24]

[DOI: 10.66224/sjrm.10.4.4]

Discussion

The purpose of presenting this case report is to describe the clinical manifestations, diagnostic process, therapeutic challenges, and outcomes of neonatal chylothorax in an extremely preterm infant with very low birth weight. Given the rarity of this condition and the complexity of its management in preterm neonates, particularly in situations where therapeutic options are limited, this report aims to emphasize the importance of early diagnosis, the role of enteral feeding in symptom exacerbation, and the necessity of a multidisciplinary approach in therapeutic decision-making. Furthermore, this case seeks to increase clinical awareness of chylothorax as a significant cause of pleural effusion in preterm infants. Neonatal chylothorax is a rare but potentially life-threatening pathological condition that may follow a more severe clinical course and be associated with a poorer prognosis in preterm infants. In these patients, structural and functional immaturity of the lymphatic system, combined with vascular fragility and the need for invasive interventions, predisposes them to the development or exacerbation of chyle leakage into the pleural space [16]. In extremely preterm neonates, even relatively small volumes of pleural effusion can result in significant impairment of pulmonary ventilation and worsening respiratory distress. One of the key clinical observations in this case was the clear temporal association between the initiation or escalation of enteral feeding and the deterioration of respiratory symptoms. Increased lymphatic flow following feeding, particularly in the presence of thoracic duct defects or obstruction, can lead to augmented chyle leakage and rapid accumulation of pleural fluid. This phenomenon underscores the importance of closely monitoring clinical changes after the initiation of enteral feeding as an important diagnostic clue in neonates admitted to the NICU [17].

From a diagnostic perspective, chylothorax in neonates may initially be misattributed to other causes of pleural effusion or worsening respiratory distress. In such circumstances, the timely use of imaging modalities such as chest radiography and thoracic ultrasonography plays a crucial role in identifying pleural effusion. Nevertheless, definitive diagnosis can only be achieved through pleural fluid analysis. The milky appearance of the fluid, together with laboratory findings such as elevated triglyceride levels and lymphocyte predominance, constitutes key diagnostic criteria that guide subsequent therapeutic management [18]. Therapeutically, management of neonatal chylothorax typically begins with a conservative approach. Cessation of enteral feeding and initiation of total parenteral nutrition, aimed at reducing chyle production and lymphatic flow, are considered the cornerstone of initial treatment. Placement of a chest tube for fluid drainage and reduction of pressure on the lung parenchyma plays a vital role, particularly in cases accompanied by severe respiratory distress. However, in extremely preterm infants, prolonged conservative management may be associated with complications such as malnutrition, immune dysfunction, and an increased risk of infection [19].

This case also highlights the significant challenges involved in decision-making regarding surgical interventions. Extremely low birth weight and clinical instability in preterm neonates often preclude invasive procedures, rendering medical or supportive therapy the only feasible options. Under these circumstances, the risk of secondary complications, including sepsis and pneumonia, is increased and may substantially and adversely affect prognosis.

In conclusion, this case report demonstrates that neonatal chylothorax in extremely preterm infants is not only a diagnostic challenge but also a complex therapeutic dilemma that requires meticulous monitoring, individualized decision-making, and close collaboration among multidisciplinary care teams. Heightened awareness of this condition in the setting of treatment-resistant respiratory distress and pleural effusion may play an important role in improving early diagnosis and optimizing the management of affected neonates.

Conclusion

Although congenital chylothorax is considered a rare condition in the neonatal period, it may be associated with a complex clinical course and potentially life-threatening outcomes in extremely preterm infants. The present report highlights that the onset or worsening of respiratory distress concurrent with the initiation or escalation of enteral feeding should be regarded as a serious warning sign and should prompt clinical suspicion of chylothorax, particularly in neonates with prolonged NICU hospitalization and a history of central venous catheter use. This case underscores the importance of timely imaging studies and meticulous pleural fluid analysis in establishing a definitive diagnosis. The milky appearance of pleural fluid, together with laboratory findings such as elevated triglyceride levels and lymphocyte predominance, represents key diagnostic features that can effectively guide therapeutic decision-making. Nevertheless, even with early diagnosis, the management of chylothorax in extremely preterm infants remains highly challenging, as therapeutic options, especially surgical interventions, are often limited by very low birth weight and clinical instability. This case report emphasizes the necessity of a multidisciplinary approach involving neonatologists, pediatric surgeons, and specialized care teams and demonstrates that conservative management, despite its central role, may be insufficient in some patients. The unfavorable outcome observed in this case further highlights the importance of close monitoring for secondary

[Downloaded from saremjrm.com on 2026-11-24]

[DOI: 10.66224/sjm.10.4.4]

complications, including immunodeficiency, infections, and sepsis. Overall, the presentation of this case may contribute to increased clinical awareness, earlier recognition, and improved therapeutic decision-making in neonatal chylothorax, particularly among extremely preterm infants, and underscores the need for further studies to optimize management strategies in this vulnerable population.

Ethical Issue

In conducting this research, all ethical principles in medical and biological research were observed in accordance with the Declaration of Helsinki, and the rights, dignity, and confidentiality of the participants were protected.

Conflict of Interests

There was no conflict of interest in this study.

Source of Funding

The costs of this project were funded by the Sarem Gynecology, Obstetrics and Infertility Research Center.

References

1. Heffner JE, Etiology, clinical presentation, and diagnosis of chylothorax. UpToDate. Post TW. Waltham, MA: UpToDate, 2022.

2. Alexander KG, Tsavala E, Mensah I, Ntontsi P, Hatzimanolis I, Metaxas E, Navigating idiopathic Chylothorax: a case report and review of the diagnosis and management. Oxford Medical Case Reports, 2025. (10).

3. Walsh M, Tutor JD, The Management of Neonatal Chylothorax. Current Treatment Options in Pediatrics, 2025. 11(1): 28.

4. Hamad AB, Regaieg C, Kolsi N, Charfi M, Bouraoui A, Hamida N, et al., Management of Congenital Chylothorax in Intensive Neonatal Care Unit in Sfax, Tunisia: A Case Series and Review of the Literature. Iranian Journal of Neonatology, 2024. 15. (1).

5. Bhatnagar M, Fisher A, Ramsaroop S, Carter A, Pippard B, Chylothorax: pathophysiology, diagnosis, and management-a comprehensive review. J Thorac Dis, 2024. 16(2): 1645-1661.

6. Tutor JD, Chylothorax in infants and children. Pediatrics, 2014. 133(4): 722-733.

7. Savla JJ, Itkin M, Rossano JW, Dori Y ,Post-Operative Chylothorax in Patients With Congenital Heart Disease. Journal of the American College of Cardiology, 2017. 69(19): 2410-2422.

8. Peediyakkal MZK, Mahmood NS, Thurakkal A, Ibrahim E, Kannappilly N, Koya SH, et al., Superior Vena Cava Thrombosis Presenting As Massive Chylothorax: A Report of a Rare Case. Cureus, 2025. 17. (16).

9. Habas E, Farfar K, Errayes A, Alfitori G, Ghazouani H, Habas A, et al., Updates on the pathophysiology and therapies of chylous pleural effusion: A narrative review. Yemen Journal of Medicine, 2023: 145-150.

10. Mathivet A, Bertrand M, Quere I, Gris J-C, Ghelfi J, Frandon J Pathophysiology of Chylous Anasarca Caused by Lymphatic Occlusion: A Case Report and Review of the Literature. Journal of Personalized Medicine, 2025. 15, 216 DOI: 10.3390/jpm15060216.

11. Dehghan K, Idiopathic chylothorax in a term neonate and successful treatment with octreotide and medium chain triglyceride-enriched formula: a case report. Journal of Pediatric Perspectives, 2019. 7(6): 9535.954..

12. Skouras V, Kalomenidis I, Chylothorax: Diagnostic approach. Current opinion in pulmonary medicine, 2010. 16: 387-93.

13. García J, Alemán C, Jáuregui A, Vázquez A, Persiva Ó, Fernández de Sevilla T, Chylothorax in Adults. Characteristics of 1 ٧Patients and a Review of the Literature. Archivos de Bronconeumología, 2017. 53(7): 407-408.

14. Walsh M, Tutor J, The Management of Neonatal Chylothorax. Current Treatment Options in Pediatrics, 2025. 11.

15. Bhagiratha S, Bandiya P, Shivanna N, Benakappa N, Congenital Chylothorax: Conservative Management Counts. J Indian Assoc Pediatr Surg, 2022. 27(5): 652-654.

16. Resch B, Sever Yildiz G, Reiterer F, Congenital Chylothorax of the Newborn: A Systematic Analysis of Published Cases between 1990 and .٢٠١٨ Respiration, 2022. 101(1): 84-96.

17. Nasr AE, Alsharaan AM, Alallah J, Premature infant with sudden respiratory distress. BMJ Case Rep, 2020. 13. (6).

[Downloaded from saremjrm.com on 2026-11-24]

[DOI: 10.66224/sjrm.10.4.4]

18. Senarathne UD, Rodrigo R, Dayanath B, Milky pleural effusion in a neonate and approach to investigating chylothorax. BMJ Case Rep, 2021. 14. (9).
19. Saeidi R, Nourizadeh S, Octreotide for the management of chylothorax in newborns, case report. Iranian Journal of Neonatology, 2015. 5(4): 37-39.

[Downloaded from saremjrm.com on 2026-11-24]

[DOI: 10.66224/sjrm.10.4.4]