Sarem Journal of Medical Research. Volume 10, Issue 4, Winter 2026: 179- 184

Ruptured Cornual Ectopic Pregnancy: A Rare Case Managed by Emergency Laparotomy and Sturmdorf Repair

ARTICLE INFO

DOI: 1052547/sjrm.10.4.2

Article Type

Case Report

Authors

Farnaz Nami[1], Mohammad Reza Nateghi[1,2]*

1- Sarem Gynecology, Obstetrics and Infertility Research Center, Sarem Women's Hospital, Iran University of Medical Science (IUMS), Tehran, Iran.
2- Sarem Cell Research Center (SCRC), Sarem Women's Hospital, Tehran, Iran.

Corresponding Authors:

Mohammad Reza Nateghi; Sarem Gynecology, Obstetrics and Infertility Research Center, Sarem Women's Hospital, Iran University of Medical Sciences, Tehran, Iran.
Address: Sarem Women Hospital, Basij Square, Phase 3, Ekbatan Town, Tehran, Iran. Postal code: 1396956111, Phone: +98 (21) 44670888, Fax: +98 (21) 44670432.

Received: 06 December 2025
Accepted: 31 January 2026
e Published: 02 February 2026

Article History

ABSTRACT

Introduction: Cornual ectopic pregnancy is one of the rarest forms of ectopic pregnancy, occurring at the interstitial portion of the fallopian tube where it traverses the muscular wall of the uterus. This type of pregnancy carries a high risk of uterine rupture and massive intra-abdominal hemorrhage and is usually diagnosed at a more advanced gestational age compared with other types of ectopic pregnancies. Early diagnosis is challenging due to its unique anatomical location, and in many cases, patients present with signs of hemodynamic shock.

Case Presentation: A 34-year-old woman, G2P1, during the lactation period, presented to the emergency department of Sarem Hospital with severe abdominal pain and pre-shock symptoms (PR:130; BP:80/50 mmHg). She had a known 12-week intrauterine pregnancy. Ultrasound revealed a large amount of free fluid and clots in the abdominal cavity. The patient underwent emergency laparotomy, during which approximately 2–2.5 liters of blood and clots were found in the peritoneal cavity, along with a 14-week fetus in the abdomen. A ruptured left cornual pregnancy with placental tissue abnormally adherent to the myometrium was identified, consistent with ruptured cornual ectopic pregnancy with placenta accreta. The uterine rupture was repaired using the Sturmdorf technique, and the left fallopian tube was completely removed. After blood transfusion and intensive care, the patient was discharged in good general condition. On follow-up, β-hCG levels were negative and hemoglobin returned to normal.

Conclusion: Cornual pregnancy, due to delayed diagnosis, may result in extensive uterine rupture and life-threatening hemorrhage. Awareness of its clinical features and the use of precise imaging modalities are essential for early diagnosis and prevention of fatal complications. Uterine repair using the Sturmdorf technique can be an effective approach in selected cases, preserving uterine function and ensuring full recovery.

Keywords: Cornual Ectopic Pregnancy; Uterine Rupture; Placenta Accreta; Sturmdorf Technique; Emergency Laparotomy; Interstitial Region (Cornual).

[Downloaded from saremjrm.com on 2026-11-24]

[DOI: 10.66224/sjrm.10.4.2]

Introduction

Cornual ectopic pregnancy (also referred to as interstitial pregnancy) is one of the rarest yet most dangerous forms of ectopic pregnancy [1]. This type of pregnancy occurs when implantation takes place in the interstitial portion of the fallopian tube, where the tube traverses the muscular wall of the uterus. Owing to the thicker surrounding myometrial layer and the rich vascular connections with both uterine and ovarian vessels, this anatomical location allows the embryo to grow for a longer period compared with typical tubal ectopic pregnancies. However, once rupture occurs, it may result in massive and life-threatening intra-abdominal hemorrhage [2,3]. Therefore, despite its low incidence relative to other types of ectopic pregnancy, cornual pregnancy carries particular clinical significance.

Clarifying the conceptual differences among the terms cornual, interstitial, and angular pregnancy is essential, as these terms are inconsistently used across the literature and may lead to diagnostic ambiguity and inconsistencies in research reporting [4]. In brief, interstitial pregnancy refers to implantation within the portion of the fallopian tube that lies embedded in the myometrium. The term cornual pregnancy is sometimes used interchangeably with this condition; however, in some sources, it refers to pregnancies located in a uterine horn, such as a rudimentary horn or a unicornuate uterus. Accurate clinical and imaging differentiation among these entities is of critical importance, as management strategies and the risk of uterine rupture differ substantially [5].

The known risk factors for cornual pregnancy are similar to those for other ectopic pregnancies and include a history of previous ectopic pregnancy, tubal damage or surgery, pelvic inflammatory disease, and the use of assisted reproductive technologies (IVF and related techniques). Nevertheless, cases without any identifiable risk factors have also been reported [6]. From a pathophysiological perspective, trophoblastic implantation in the interstitial region, due to the distinct characteristics of the endometrium and myometrium and their association with muscular layers, may exhibit a more aggressive invasive pattern, which in some cases leads to abnormal placental adherence. This abnormal placental invasion is associated with a markedly increased risk of hemorrhage during placental removal or surgical repair [7]. Although placental adherence at ectopic implantation sites is rare, it represents a clinically significant condition that complicates surgical management.

Clinically, timely diagnosis of cornual pregnancy remains challenging. Patients may present with localized or diffuse abdominal pain, vaginal bleeding, or remain asymptomatic until rupture occurs. Rupture is typically accompanied by signs of hemodynamic shock and is often the first critical manifestation [8]. In the screening and evaluation of suspected cases, transvaginal ultrasonography plays a pivotal role. Key sonographic findings include an eccentrically located gestational sac distant from the central uterine cavity, the *interstitial line sign* (an echogenic line connecting the uterine cavity to the gestational sac), and thinning of the surrounding myometrial mantle. Color Doppler imaging may demonstrate a peripheral hypervascular pattern known as the *ring of fire*, although this finding is not specific. In cases where differentiation from an eccentrically implanted intrauterine pregnancy or a pregnancy within a uterine horn is difficult, additional imaging with magnetic resonance imaging (MRI) can provide more detailed anatomical information and assist in therapeutic decision-making [9,10].

The therapeutic approach to cornual pregnancy should be individualized based on the patient's hemodynamic status, gestational age, size and location of the lesion, and desire for future fertility. In hemodynamically stable patients with early diagnosis, non-surgical options such as systemic methotrexate administration or ultrasound-guided local injection into the trophoblast may be considered in selected cases. However, the success rate of medical management decreases with advancing gestational age and larger lesion size [11]. Minimally invasive surgical approaches, including laparoscopic cornuostomy or limited local resection, may also be feasible in carefully selected patients. In contrast, in cases of rupture with massive hemorrhage, emergency laparotomy is unavoidable for hemostatic control, removal of damaged tissue, and, if necessary, hysterectomy. Uterine preservation in the setting of severe bleeding requires rapid decision-making and the application of reconstructive techniques, often combined with adjunctive hemorrhage-control measures such as uterine artery embolization, layered reinforcing sutures, and blood transfusion when indicated [12].

Beyond immediate treatment considerations, future fertility outcomes and risks in subsequent pregnancies represent additional clinical challenges. Following interstitial repair or cornulectomy, patients require close monitoring in future pregnancies, as the repaired site may be at increased risk of uterine rupture or other obstetric complications. Decisions regarding the mode and timing of delivery should be individualized based on patient-specific factors and the characteristics of the prior surgery [13].

The aim of this case report is to present a comprehensive description of a rare case of ruptured cornual pregnancy at 14 weeks of gestation, complicated by placental adherence (placenta accreta), which was successfully managed by emergency laparotomy and reconstructive techniques, including Sturmdorf repair, without the need for hysterectomy. This report seeks to elucidate diagnostic challenges, imaging limitations in early detection, and surgical options for uterine preservation, while highlighting

[Downloaded from saremjrm.com on 2026-11-24]

[DOI: 10.66224/sjm.10.4.2]

practical considerations for managing similar cases in emergency settings. Furthermore, it emphasizes that even in the absence of classic risk factors, the possibility of cornual pregnancy and its association with placental adherence disorders should be considered in patients presenting with abdominal pain and inconclusive sonographic findings, in order to prevent diagnostic delay and life-threatening outcomes.

Case Presentation

Demographic Information and Clinical Background

A 34-year-old woman, gravida 2 para 1 (G2P1), who was in the lactation period, presented to Sarem Women's Tertiary Hospital in Tehran. Her medical records revealed no significant underlying medical conditions or history of prior surgical procedures.

History and Timeline of Events

Approximately two weeks prior to presentation, the patient had become aware of her pregnancy, which, according to her report, had been diagnosed as a 12-week intrauterine pregnancy. On 03/05/1404 (Iranian calendar), she presented to the emergency department with severe abdominal pain accompanied by signs of hemodynamic instability, including palpitations and pre-shock symptoms.

Clinical Examination and Initial Paraclinical Findings

Upon admission, the patient's vital signs revealed a heart rate of 130 beats per minute and a blood pressure of 80/50 mmHg, consistent with a hypovolemic/pre-shock state. Laboratory evaluation demonstrated severe anemia, with a hemoglobin level of 5.7 g/dL. An urgent bedside ultrasound examination performed in the emergency department revealed a large volume of free fluid with extensive clots within the peritoneal cavity and pelvis. Considering the patient's hemodynamic instability, sonographic findings, and pregnancy history, the initial clinical diagnosis was intra-abdominal hemorrhage secondary to a ruptured ectopic pregnancy.

Therapeutic Decision-Making and Preoperative Management

In light of the patient's hemodynamic shock and profound anemia, she was immediately prepared for emergency laparotomy. Initial resuscitative measures included intravenous fluid administration and preparation of blood products for transfusion.

Intraoperative Findings and Surgical Intervention

During emergency laparotomy, approximately 2–2.5 liters of blood and dense clots were identified within the peritoneal cavity. A fetus was found freely within the abdominal cavity, with size and morphological features corresponding to a gestational age of approximately 14 weeks. The site of rupture was identified in the left interstitial (cornual) region of the uterus. Portions of placental tissue were found to be adherent to the myometrium, indicating placental invasion into the myometrial layer, which was pathologically consistent with abnormal placental adherence (placenta accreta).

To control hemorrhage and repair the defect, the rupture in the interstitial region of the uterus was reconstructed using the Sturmdorf repair technique. In addition, the left fallopian tube was completely excised. During surgery, the patient received two units of packed red blood cells. Following adequate hemostasis and stabilization of hemodynamic parameters, the patient was transferred to the intensive care unit (ICU).

Postoperative Course and Pathological Findings

After receiving intensive postoperative care, the patient demonstrated a favorable recovery and was discharged on 07/05/1404 in good general condition, with a hemoglobin level of 7.7 g/dL. Histopathological examination of the submitted specimens confirmed a ruptured cornual ectopic pregnancy with villous invasion into the myometrium, showing features consistent with placenta accreta. During outpatient follow-up on 25/05/1404, serum β-hCG levels were reported as negative, and the patient's hemoglobin level had increased to 11.9 g/dL.

Clinical Considerations Related to This Case

- This case represents a ruptured cornual ectopic pregnancy that progressed to a relatively advanced gestational age (approximately 14 weeks), which is unusual for ectopic pregnancies and suggests delayed diagnosis or atypical growth within the interstitial region.
- The presence of adherent placental tissue (placenta accreta) in a cornual pregnancy contributed to an increased risk of hemorrhage and difficulty in placental separation. In this patient, complete resection of the left fallopian tube and surgical repair of the rupture were performed with the aim of hemorrhage control and uterine preservation. The operative notes did not explicitly state the precise rationale for complete salpingectomy; however, it was most likely undertaken to eliminate the source of bleeding and remove damaged tissue.
- The choice of uterine repair using the Sturmdorf technique played a crucial role in preserving uterine integrity and preventing hysterectomy in this case, which is particularly important with regard to maintaining future fertility potential, provided that uterine function is preserved.

[Downloaded from saremjrm.com on 2026-11-24]

[DOI: 10.66224/sjrm.10.4.2]

Nevertheless, surgical decision-making must be individualized based on the extent of uterine tissue destruction, severity of hemorrhage, and the patient's hemodynamic status.

Summary of Key Findings

The patient presented with a ruptured left-sided cornual ectopic pregnancy complicated by massive intra-abdominal hemorrhage (estimated blood loss of 2–2.5 liters), severe anemia, and a pre-shock state. Emergency surgical management included laparotomy, repair of the uterine rupture using Sturmdorf sutures, left salpingectomy, and transfusion of two units of packed red blood cells. Histopathological findings were consistent with a cornual ectopic pregnancy complicated by placenta accreta. Follow-up evaluations demonstrated stabilization of hemoglobin levels and negative serum β-hCG.

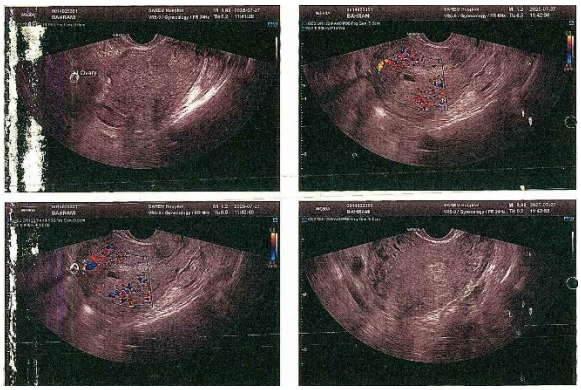

Figure 1. Transvaginal ultrasonographic image of the uterus and left interstitial region demonstrating a hypoechoic mass in the cornual area with increased vascularity on color Doppler examination.

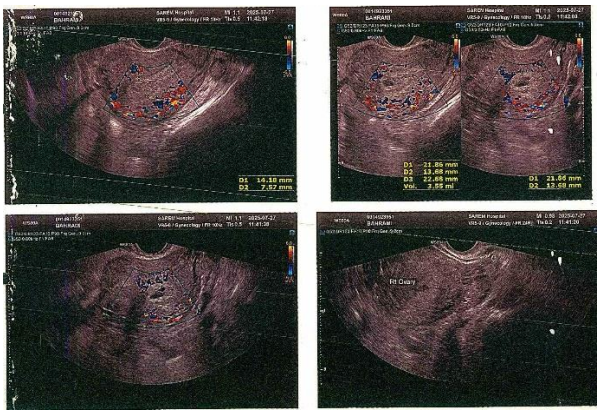

Figure 2. Color Doppler image of the same lesion in the uterine cornual region, showing a peripheral hypervascular pattern (*ring of fire sign*), a characteristic feature of ectopic pregnancy.

Discussion

Cornual or interstitial pregnancy is one of the rarest forms of ectopic pregnancy, accounting for only approximately 2–4% of all ectopic pregnancies [14]. In this condition, the fertilized ovum implants within the interstitial portion of the fallopian tube, where the uterine myometrial layer is thicker. This anatomical characteristic allows the pregnancy to progress for a longer duration before rupture occurs. Consequently, unlike other ectopic pregnancies, which typically rupture between 6 and 8 weeks of gestation, rupture in cornual pregnancy may occur during the second trimester or even later [15].

Clinical manifestations are often nonspecific and may include abdominal pain, mild vaginal bleeding, or an absence of symptoms until rupture occurs. In the present case, diagnosis was delayed until uterine rupture, and the patient presented with signs of hemodynamic shock and profoundly low hemoglobin levels [16]. This finding highlights the critical importance of early diagnosis and heightened clinical vigilance in pregnant patients presenting with abdominal pain, even in cases where initial ultrasonography appears to demonstrate an intrauterine pregnancy. In such circumstances, meticulous transvaginal ultrasonography with color Doppler assessment, and MRI when necessary, can be valuable tools in differentiating cornual pregnancy from pseudo–intrauterine pregnancy.

From a therapeutic perspective, management of cornual pregnancy depends on multiple factors, including hemodynamic stability, the patient's desire for fertility preservation, and the size and status of the lesion. In hemodynamically stable cases, options such as local or systemic methotrexate administration, laparoscopic surgery, or limited uterine resection may be considered. However, in cases of rupture accompanied by massive hemorrhage, such as the present case, emergency laparotomy is unavoidable. In our patient, extensive uterine rupture and the presence of adherent placental tissue posed significant intraoperative challenges [17].

A noteworthy aspect of this case was the selection of the Sturmdorf repair technique for uterine reconstruction. Although this technique is traditionally used in cervical surgery, it was applied here to reconstruct the ruptured uterine layers with the aim of preserving uterine integrity. This approach likely contributed to avoiding hysterectomy and maintaining the patient's future fertility potential [18]. In limited similar reports, successful uterine repair using comparable techniques has been associated with the resumption of normal menstruation and even subsequent successful pregnancies.

The coexistence of placenta accreta in cornual pregnancy is a rare but highly dangerous finding, characterized by deep invasion of chorionic villi into the myometrium and a substantially increased risk of hemorrhage [19,20]. In the present patient, this condition

[Downloaded from saremjrm.com on 2026-11-24]

[DOI: 10.66224/sjrm.10.4.2]

likely played a major role in the severity of intra-abdominal bleeding. This observation underscores the importance of considering the possibility of abnormal placental adherence in any ectopic pregnancy that progress to an advanced gestational age. Overall, this case report emphasizes the vital importance of timely diagnosis, rapid intervention, and appropriate surgical strategy selection to preserve the uterus. Clinical awareness among obstetricians and emergency physicians regarding this rare condition plays a crucial role in reducing maternal morbidity and mortality.

Conclusion

Cornual pregnancy represents one of the most challenging forms of ectopic pregnancy and is often diagnosed at advanced stages of gestation, where it may be associated with severe uterine rupture and life-threatening hemorrhage. Early diagnosis using precise imaging modalities—particularly transvaginal ultrasonography with color Doppler—can help prevent fatal complications. In cases of rupture, prompt and effective surgical management is essential. Uterine repair using the Sturmdorf technique, in carefully selected patients, may serve as an effective alternative to hysterectomy, allowing hemorrhage control while preserving future fertility. The present report illustrates the successful clinical application of this approach in a case of ruptured cornual pregnancy complicated by placenta accreta.

Ethical Issue

In conducting this research, all ethical principles in medical and biological research were observed in accordance with the Declaration of Helsinki, and the rights, dignity, and confidentiality of the participants were protected.

Conflict of Interests

There was no conflict of interest in this study.

Source of Funding

The costs of this project were funded by the Sarem Gynecology, Obstetrics and Infertility Research Center.

References

1. Dagar M, Srivastava M, Ganguli I, Bhardwaj P, Sharma N, Chawla D. Interstitial and Cornual Ectopic Pregnancy: Conservative Surgical and Medical Management. Journal of obstetrics and gynaecology of India. 2018;68(6):471-6.
2. Gaetani M, Di Gennaro D, Vimercati A, Vitagliano A, Dellino M, Malvasi A, et al. Cornual Pregnancy. Gynecol Minim Invasive Ther. 2023;12(3):130-4
3. Yalçın Y, Tatar B, Erdemoğlu E, Akkurt MÖ, Erdemoğlu E. İnterstisyel gebelikte kornual rezeksiyon için laparoskopik sistemik uterin korn devaskülarizasyonu. Turkish journal of obstetrics and gynecology. 2015;12(3): 182 - 4.
4. Dhanju G, Goubran A, Zimolag L, Chartrand R, Matthew F, Breddam A. Distinguishing between cornual, angular and interstitial ectopic pregnancy: A case report and a brief literature review. Radiol Case Rep. 2023;18(7):2531-44.
5. Yaman C. Cornual pregnancy and interstitial pregnancy. Journal of the Turkish German Gynecological Association. 2011;12(1):61.
6. Perkins KM, Boulet SL, Kissin DM, Jamieson DJ. Risk of ectopic pregnancy associated with assisted reproductive technology in the United States, 2001-2011. Obstetrics and gynecology. 2015;125(1):70-8.
7. Jauniaux E, Burton G. Pathophysiology of Placenta Accreta Spectrum Disorders: A Review of Current Findings. Clinical Obstetrics and Gynecology. 2018;61:1.
8. Mullany K, Minneci M, Monjazeb R, O CC. Overview of ectopic pregnancy diagnosis, management, and innovation. Women's health (London, England). 2023;19:17455057231160349.
9. Abeyak M. Role of Transvaginal Ultrasound in Ectopic Pregnancy Diagnosis2024.
10. Thom C, Livingstone K, Ottenhoff J, Han D, Martindale J, Moak J. Comparison of transvaginal ultrasound utilization between radiology and point of care ultrasound in first trimester pregnancy. The American Journal of Emergency Medicine. 2024;80:143-8.

[Downloaded from saremjrm.com on 2026-11-24]

[DOI: 10.66224/sjrm.10.4.2]

11. Loukopoulos T, Zikopoulos A, Mastora E, Galani A, Stavros S, Kolibianakis E. Multidose methotrexate treatment of cornual pregnancy after in vitro fertilization: Two case reports. Case reports in women's health. 2022;33:e00376.

12. Ayoubi JM, Carbonnel M, Pirtea P, Kvarnström N, Brännström M, Dahm-Kähler P. Laparotomy or minimal invasive surgery in uterus transplantation: a comparison. Fertility and sterility. 2019;112(1):11-8.

13. Sugai S, Sasabuchi Y, Yasunaga H, Isogai T, Yoshihara K, Nishijima K. In-hospital outcomes of repair and hysterectomy for uterine rupture: A nationwide observational study. European journal of obstetrics, gynecology, and reproductive biology. 2024;302:196-200.

14. Bolaji I, Yandra A, Awoniyi MO, Igbenehi CN. Two case reports of triple ectopic: Literature review of incidence, risk factors and management of recurrent ectopic pregnancy. Ultrasound. 2025;33(3):168-75

15. Lamuwalla M, Panjwani S, Ismail A, Samji S, Kaguta M, Jaiswal S .Interstitial ectopic pregnancy, a rare clinical phenomenon diagnosed asymptomatically on routine work up in Tanzania: Case report. International journal of surgery case reports. 2025;126:110688.

16. Papageorgiou D, Sapantzoglou I, Prokopakis I, Zachariou E. Tubal Ectopic Pregnancy: From Diagnosis to Treatment. Biomedicines. 2025;13(6):1465.

17. Mikhitarian M, Goodnight Iii W, Keefe N. Local Methotrexate Plus Uterine Artery Embolization for High-Risk Interstitial Ectopic Pregnancy. Seminars in interventional radiology. 2023;40(4):357-61.

18. Liu X, Zhang X, Hua K. Restore the Continuity of Uterus-Cervix-Vagina for Cervical Restenosis after Cervicovaginal Reconstruction: A Case Report. Gynecol Minim Invasive Ther. 2025;14(2):182-4.

19. Mohr-Sasson A, Timor I, Meyer R, Stockheim D, Orvieto R, Mashiach R. Placenta accreta spectrum in subsequent pregnancy following myomectomy. The journal of maternal-fetal & neonatal medicine : the official journal of the European Association of Perinatal Medicine, the Federation of Asia and Oceania Perinatal Societies, the International Society of Perinatal Obstet. 2022;35(22):4332-7.

20. Yarandi F, Eftekhar Z, Shojaei H, Rahimi-Sharbaf F, Baradaran F. Conservative management of placenta increta: case report and literature review. Acta Medica Iranica. 2011:396-8.

[Downloaded from saremjrm.com on 2026-11-24]

[DOI: 10.66224/sjrm.10.4.2]