

Maxillary Sinus Squamous Cell Carcinoma with Orbit Extension; A Case Report

Running Head: A Case Report of Maxillary Sinus SCC

ARTICLE INFO

Article Type

Case Report

Authors

Hamidreza Hasani^{1,2}, Marjan Razi-Khosroshahi³, Shayan Mardi^{4*}, Mahmoud Soltani⁵

¹ Eye Research Center, The Five Senses Institute, Rasoul Akram Hospital, Iran University of Medical Sciences, Tehran, Iran

² Department of Ophthalmology, Madani Hospital, Alborz University of Medical Sciences, Karaj, Iran

³ Student Research Committee, Iran University of Medical Sciences, Tehran, Iran

⁴ Student Research Committee, Arak University of Medical Sciences, Arak, Iran

⁵ Student Research Committee, Tehran Medical Sciences, Islamic Azad University, Tehran, Iran

*Corresponding Author:

Shayan Mardi, MD
Student Research Committee, Arak University of Medical Sciences, Arak, Iran
Email: p.mardi.med@gmail.com
Tel: +989120560191

ABSTRACT

Introduction: Squamous cell carcinoma of the maxillary sinus is a rare, highly aggressive neoplasm that invades the surrounding tissues and other sinuses. this disease is characterized by various non-specific signs and symptoms, which may lead to delayed diagnosis and poor outcomes.

Case: The patient presented to our clinic at advanced stages of the disease and underwent an operation.

Keywords: SCC Tumors, Orbit Extension, Case report

Received: 01 August, 2022
Accepted: 01 September, 2022
e Published: 26 March, 2023

Article History

Copyright© 2021, ASP Ins. This open-access article is published under the terms of the Creative Commons Attribution-Noncommercial 4.0 International License which permits Share (copy and distribute the material in any medium or format) and Adapt (remix, transform, and build upon the material) under the Attribution-Noncommercial terms.

کارسینوم سلول سنگفرشی سینوس ماگزیلاری با اربیت اکستنشن. گزارش موردی

حمیدرضا حسنی^{۱*}، مرجان رازی خسروشاهی^۳، شایان مردی^۴، محمد سلطانی^۵

^۱ مرکز تحقیقات چشم، موسسه حواس پنجگانه، بیمارستان رسول اکرم، دانشگاه علوم پزشکی ایران، تهران، ایران

^۲ گروه چشم پزشکی، بیمارستان مدنی، دانشگاه علوم پزشکی البرز، کرج، ایران

^۳ کمیته تحقیقات دانشجویی، دانشگاه علوم پزشکی ایران، تهران، ایران

^۴ کمیته تحقیقات دانشجویی، دانشگاه علوم پزشکی اراک، اراک، ایران

^۵ کمیته تحقیقات دانشجویی، علوم پزشکی تهران، دانشگاه آزاد اسلامی، تهران، ایران

چکیده

مقدمه: کارسینوم سلول سنگفرشی سینوس ماگزیلاری یک نئوپلاسم نادر و بسیار تهاجمی است که به بافت های اطراف و سایر سینوس ها حمله می کند. این بیماری با علائم و نشانه های غیر اختصاصی مختلفی مشخص می شود که ممکن است منجر به تاخیر در تشخیص و نتایج ضعیف شود. **مورد:** بیمار در مراحل پیشرفته بیماری به کلینیک ما مراجعه کرد و تحت عمل جراحی قرار گرفت.

کلید واژه ها: تومورهای SCC، اربیت اکستنشن، گزارش مورد

تاریخ دریافت: ۱۴۰۱/۰۵/۱۰

تاریخ پذیرش: ۱۴۰۱/۰۶/۱۰

*نویسنده مسئول: دکتر شایان مردی

کمیته تحقیقات دانشجویی، دانشکده پزشکی، دانشگاه علوم پزشکی اراک، اراک، ایران

Introduction

Sino-nasal neoplasms account for 3-5% of head neck cancers [1]. Squamous cell carcinoma of head and neck comprises the most common neoplasm with a frequency of 80-90 % [2]. The maxillary sinus is affected the most among all these cancers [3] and has a relatively high incidence among Asian races [4]. Possible predisposing factors that can potentially increase the risk of malignancy include occupational exposure to Asbestos and arsenic, nickel compounds inhalation, heating gases, and smoking [5]. As this condition manifests with non-significant and non-bothersome symptoms, it is often ignored and not diagnosed until late progressive stages of the disease and causes morbidity and mortality. In this study, a middle-aged man with SCC of the maxillary sinus with extension to orbit, which eventually underwent complete exenteration, is reported.

Case Presentation

A 50 year-old-male presented to our clinic with loss of vision, proptosis of his right eye, and mild swelling in the right zygomatic region. His symptoms have progressed within ten days before admission. The patient had a history of diabetes, chronic kidney disease, hypertension, and hypothyroidism. He reported the history of cataract surgery, and intravitreal Bevacizumab injection following diabetic retinopathy. The patient stated that he suffered from mild pain in the right eye, mild headache, epiphora, nasal obstruction, postnasal discharge, and rhinitis for last month. He was not complaining of nasal or oral ulcers. He was a smoker with a twenty pack-year history of smoking.

Right eye physical examination revealed proptosis, hypo-opthalmos, severe lower lid chemosis, corneal edema, iris atrophy, and a tumor-like lesion (Figure1). Severe non-proliferative diabetic retinopathy was identified in the left eye. The examination also revealed posterior chamber intraocular lenses and posterior capsular opacification in both eyes. The right eye had no light perception, and the left eye had a visual acuity of 7/10. The right zygomatic region was mildly tender, and an obstruction and moderate paresthesia were identified in the right maxillary area. The oral and nasal examination did not reveal any oral ulcers or teeth involvement, and no lymphadenopathy was detected.

The inferior, posterior, lateral, and medial walls of the right maxillary sinus were involved in skull imaging. CT scan revealed a lesion in maxillary sinus with extension to the orbital cavity destroying the inferior and medial walls of the orbit in favor of maxillary squamous cell carcinoma with extension to orbit (Figure 2). The excisional biopsy revealed well-differentiated squamous cell carcinoma with necrosis, moderate to severe inflammation, and impossible surgical margin evaluation. The patient underwent maxillectomy with total orbital exenteration. Postoperatively, he received Ceftazidime one gram intravenously, twice daily and oral Acetaminophen codein 500 mg, twice daily. Three weeks later, he received radiation therapy for 30 sessions after surgery.

Follow-up and Outcomes: Four months later, the patient was hospitalized due to abscess formation in the right maxillary sinus. He underwent antibiotic therapy. Two weeks later, the abscess disappeared, and the patient was relieved uneventfully. An MRI study revealed postoperative changes. No residue or pathologic enhancement were identified. The patient underwent reconstruction surgery.

Surgical procedure: Initially, tarsorrhaphy 4-0 traction sutures were placed on the right eyelids of the patient. The incision through the skin and orbicularis oculi muscle was made using cautery at the orbital rim. Inferior and lateral dissection of the eye was carried out. The supraorbital, anterior, and posterior ethmoidal neurovascular bundles were identified and cauterized. Then the ophthalmic artery was transected, and hemostasis was attained. Biopsies of orbit, maxilla, and posterior margin were obtained and sent for frozen section evaluation. As eyelids were intact Lid Sparing Exenteration Technique was decided and performed (Figure 3). The ocular region was reconstructed by an acrylic 3D printed ocular prosthesis. An RTV medical grade silicon with shore 40 was also used for facial reconstruction attached by factor II medical silicone adhesive to the patient's face (Figure 4).

Discussion

Squamous cell carcinoma arising from maxillary sinus is a rare neoplasm (0.2-0.8% of all human malignant neoplasms) that is considered to have a poor prognosis. Due to the low incidence of this cancer, and the high costs of its diagnosis, screening is not affordable for health services.

Maxillary SCC is potentially life-threatening and can lead to orbital exenteration. Reconstructive surgeries seem to reduce the psychiatric burden of orbital exenteration. In this case, an acrylic 3D painted ocular prosthesis was used owing to cosmetic circumstances.

Although conducting an orbital extraction is necessary for inhibition of tumor recurrence, Anupma Kumar et al. emphasize the importance of individualized surgical treatment strategy for complex orbital cases as SCC [6]. One of the most crucial post-treatment steps in any cancer is rehabilitation. Rehabilitation is not only useful for improved cosmetic appearance but also helps the patient to improve physiological and social functions [7]. In this case, it was important to cover the defect of the nasal cavity with a prosthesis to improve breathing, and swallowing function, as well as covering the frontal segment of the brain with the facial prosthesis. Bone grafting, titanium plate, acrylic plate, and stereolithography were the cosmetic choices. Researches have shown that using 3D acrylic prosthesis, amended the clinical outcomes of orbital and maxillofacial surgery [8,9]. Bindhoo et al., in a case report, explained details of the reconstructive management of a patient following an en-bloc removal of an eye by fabricating a sectional two-piece orbital prosthesis. This procedure improved the patient's self-image and personality [10]. A study conducted by Gunjan Pruthi et al. reported a patient with a history of bilateral orbital exenteration due to squamous cell carcinoma. In their case report, a spectacle retained acrylic prosthesis with manual dexterity was used due to a complete lack of vision, utilizing a user-friendly and economical technique for the patient [11].

In our patient, a factor II medical silicone adhesive has been used for attachment of the prosthesis to the patient's face. An alternative choice is magnets, the same as what Pattanaik et al. used to manage their patient. They used rare-earth magnets for secondary retention of prosthesis on the patient's face. Their technique resulted in improved function, esthetics, and comfort [12].

The initial diagnosis of the patient (because of his diabetes) was Mucormycosis, but a biopsy revealed squamous cell carcinoma. The present study suggests that SCC should be considered as a differential diagnosis in immunocompromised patients, including patients with diabetes. This study strongly recommends biopsy and a precise pathological study in similar cases.

Declarations

Ethics approval and consent to participate: Not applicable

Consent for publication: An informed written consent was taken from the patient for publishing his data.

Availability of data and materials: No data have been submitted to any open-access databases. All data supporting the study are presented in the manuscript or available upon request.

Competing interests: All authors declare no conflict of interest

Funding: None

Acknowledgment: Not applicable.

References

1. Arnold A, Ziglinas P, Ochs K, Alter N, Geretschlager A, Ladrach K, et al. Therapy options and long-term results of sinonasal malignancies. *Oral oncology*. 2012;48(10):1031-7.
2. Sanghvi S, Khan MN, Patel NR, Yeldandi S, Baredes S, Eloy JA. Epidemiology of sinonasal squamous cell carcinoma: a comprehensive analysis of 4994 patients. *The Laryngoscope*. 2014;124(1):76-83.
3. Turner JH, Reh DD. Incidence and survival in patients with sinonasal cancer: a historical analysis of population-based data. *Head & neck*. 2012;34(6):877-85.
4. Sharma S, Sharma S, Singhal S, Mehra Y, Gupta B, Ghoshal S, et al. Carcinoma of the maxillary antrum—A 10 year experience. *Indian Journal of Otolaryngology*. 1991;43(4):191-4.
5. Kuijpers JHL, Louwman MW, Peters R, Janssens GO, Burdorf AL, Coebergh J-WW. Trends in sinonasal cancer in The Netherlands: More squamous cell cancer, less adenocarcinoma: A population-based study 1973–2009. *European journal of cancer*. 2012;48(15):2369-74.
6. Kumar A, Hsuan JD. Globe preservation surgery for a paranasal tumor with orbital extension. *Orbit*. 2010;29(6):341-2.
7. Gliklich RE, Rounds MF, Cheney ML, Varvares MA. Combining free flap reconstruction and craniofacial prosthetic technique for orbit, scalp, and temporal defects. *The Laryngoscope*. 1998;108(4):482-7.
8. Mehra P, Miner J, D'Innocenzo R, Nadershah M. Use of 3-d stereolithographic

models in oral and maxillofacial surgery. Journal of maxillofacial and oral surgery. 2011;10(1):6-13.

9. Pruthi G, Jain V, Rajendiran S, Jha R. Prosthetic rehabilitation after orbital exenteration: A case series. Indian journal of ophthalmology. 2014;62(5):629.

10. Bindhoo Y, Aruna U. Prosthetic rehabilitation of an orbital defect: A case report. The Journal of Indian Prosthetic Society. 2011;11(4):258.

11. Pruthi G, Jain V. Light weight prosthesis for a patient with bilateral orbital exenteration—A clinical report. Journal of prosthodontic research. 2013;57(2):135-9.

12. Pattanaik S, Wadkar AP. Rehabilitation of a patient with an intra oral prosthesis and an extra oral orbital prosthesis retained with magnets. The Journal of Indian Prosthetic Society. 2012;12(1):45-50.

Figure 1. patient appearance at the first visit

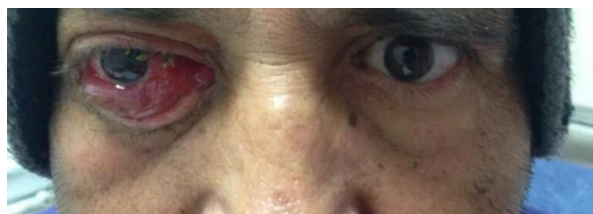

Figure 2. Axial and coronal slice of patient CT scan

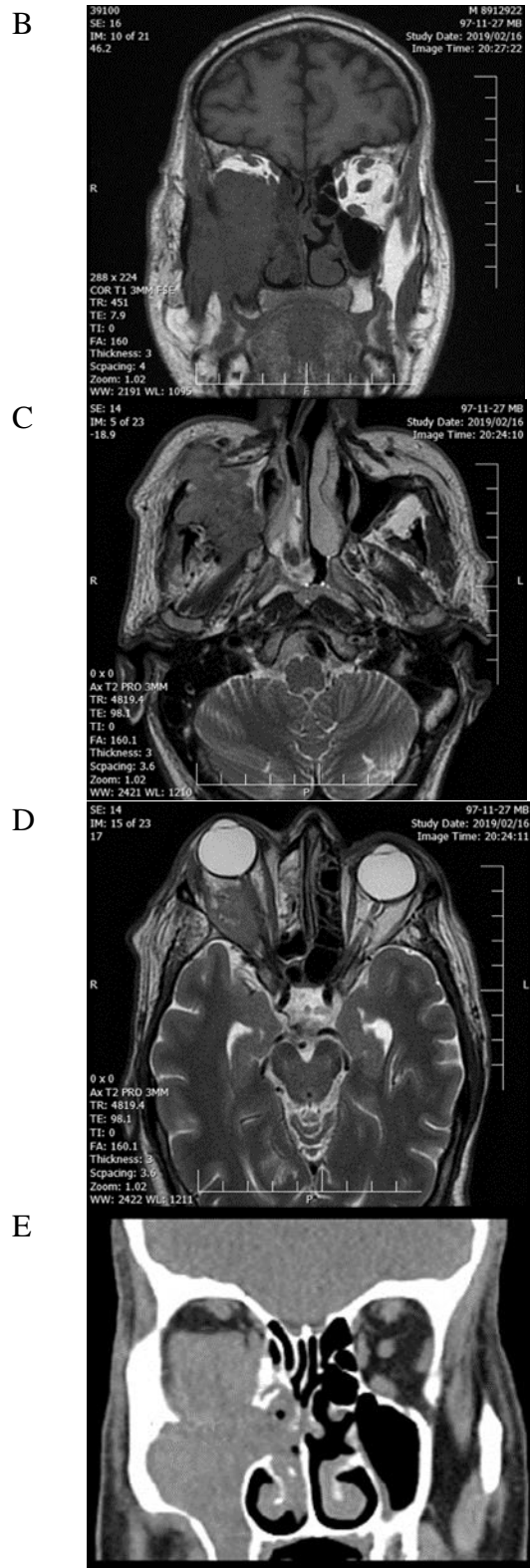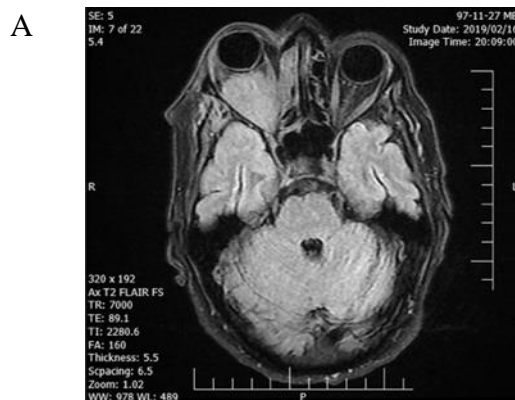


Figure 3. Patient appearance after orbital Extension.

