SJMR SAREM JOURNAL OF MEDICAL RESEARCH

Sarem Journal of Medical Research. Volume 5, Issue 4, winter 2021: 212-218

The Safety and Complications of "Z-entry" Technique of Trocar Insertion in Laparoscopic Gynecological Surgery

ARTICLE INFO

Article Type
Original article

Authors

AboTaleb Saremi [1*], MD
Mohammad Reza Nateghi[1], MD

[1] Sarem Fertility & Infertility Research Center (SAFIR) & Sarem Cell Research Center (SCRC), Sarem Women's Hospital, Iran University of Medical Science (IUMS), Tehran, Iran.

Corresponding Author

Address: Sarem Women Hospital, Basij Square, Phase 3, EkbatanTown, Tehran, Iran. Postal code:1396956111
Phone: +98 (21) 44670888
Fax: +98 (21) 44670432
Dr.saremi@sarem.org

Article History
Received: February 15, 2021
Accepted: March 08, 2021
e Published: September 29, 2021

ABSTRACT

Background and Aims: Laparoscopy is a minimally invasive surgical technique for abdominal and gynecological surgeries. To access the internal organs through the abdominal wall, a special tool called a trocar is used. The trocar enters the abdomen using a variety of techniques. The aim of this study was to evaluate the safety and possible complications of trocar insertion into the abdomen for gynecological laparoscopy using the "Z-entry" method.
Methods: From March 2018 to March 2020, 435 patients underwent laparoscopic gynecological surgery in Sarem Women's Hospital that in terms of the consequences of trocar entering the abdomen with the "Z-entry" technique, including visceral injury, vascular injury, umbilical hernia, hematoma, massive hemorrhage, infection, and mortality induced by trocar insertion, were evaluated. The results were analyzed and reported in the form of descriptive statistics and frequency distribution tables with SPSS statistical software.
Findings: This study showed that the rate of complications and problems due to insertion of trocar by "Z-entry" method was very low in these patients, so that only one case of infection (0.2%), one case of hematoma (0.2%), one case of trocar entry into blood vessels (0.2 %) and two cases (0.4%) of trocar entry into the viscera were seen. However, no cases of umbilical hernia, massive hemorrhage, and death induced by trocar insertion were found.
Conclusion: Insertion of trocar by the "Z-entry" method in laparoscopic gynecological surgeries is associated with minimal problems and complications and therefore this technique can be used as a safe method to insert trocar into the abdomen in laparoscopic surgeries.

Keywords: Laparoscopic Gynecological Surgery; Trocar Insertion; "Z-entry" Technique; Safety; Complication.

Copyright© 2021, ASP Ins. This open-access article is published under the terms of the Creative Commons Attribution-Noncommercial 4.0 International License which permits Share (copy and distribute the material in any medium or format) and Adapt (remix, transform, and build upon the material) under the Attribution-Noncommercial terms

[Downloaded from saremjrm.com on 2026-08-24]

[DOI: 10.52547/sjrm.5.4.212]

Introduction

For the first time in 1910, Hans-Christian Jacobaeus[1] performed the first clinical laparoscopic surgery in Stockholm, Sweden (1,2). Laparoscopy is a minimally invasive surgical (MIS) technique for abdominal and gynecologic surgeries, in which a special device called a "trocar" is used to access the internal organs through the abdominal wall (3). Laparoscopic gynecologic surgery is known as one of the preferred surgical methods in the world due to its low complications and shorter postoperative recovery period (4). The entrance to the abdominal cavity is done with the trocar tool, with two techniques, open and closed. In the open technique (Hasson method), the abdominal wall and peritoneal is opened with an incision below the umbilicus and the trocar enters the abdominal cavity directly from this area, vertically (5,6). In the closed technique (Veress Needle), about 3-4 liters of carbon dioxide gas is blown into the abdominal cavity by a needle for better vision and easier access to the abdominal organs, which leads to pneumoperitoneum (7,8). The trocar then enters the abdomen through a hole created by the Veress needle, approximately 1 cm below the umbilicus (3). Complications such as intestinal and visceral injuries, vascular injuries, bleeding and hematoma around the trocar site, umbilical hernia[2], and infection may occur as the trocar enters the abdomen. However, many of these complications, including vascular and visceral injury, are rare (3,10-12). At present, the evidence was insufficient to show a major difference between these two techniques (open and closed) of trocar entry into the abdominal cavity, in the rate of entry failure, vascular injury, visceral injury, or other major complications (9). Serious problems or even death are possible if the surgeon or patient does not notice the early symptoms of complications and does not treat them in a timely manner (11,13).

The "Z-entry" Technique of Trocar Insertion

In this method, which is a closed technique, instead of inserting the trocar directly (vertically) into the abdominal cavity, the trocar is first guided transversely at an angle of 45 degrees below the umbilical slit to the surgeon's assistant side, that usually after 4-5 centimeter reaches the fascia and with a little more pressure, the mandarin tip enters the fascia and then, keeping the transverse path and maintaining the pressure of the hand, the trocar returns to the surgeon side. The trocar is then directed at a 45-degree angle to the other side of the abdomen (the surgeon's assistant side) to pass through the muscle. The trocar now returns to the umbilicus and enters the abdominal cavity with low pressure (Figure 1). In this technique, in the first stage, the fascia is perforated 4-5 cm away from the umbilical site entrance. In the second stage, the trocar passes 4-5 cm away from the umbilicus on the opposite side, through the muscle, and in the third stage, the peritoneum is perforated. Forasmuch as in this method, the trocar enters the abdominal cavity almost horizontally, compared to other entry methods, in which the trocar enters the abdominal cavity vertically, the possibility of damage to arteries and organs is much less, and also in this method no need for the clamp to retract the abdominal wall, therefore the incidence of bleeding and hematoma reduced. On the other hand, due to the distances created between the entry points of the trocar in different parts including fascia, rectus abdominis muscle, and peritoneum, the possibility of umbilical hernia is very low. This technique has been used for the first time in Iran since 1995 by the author (Figures 2 to 9).

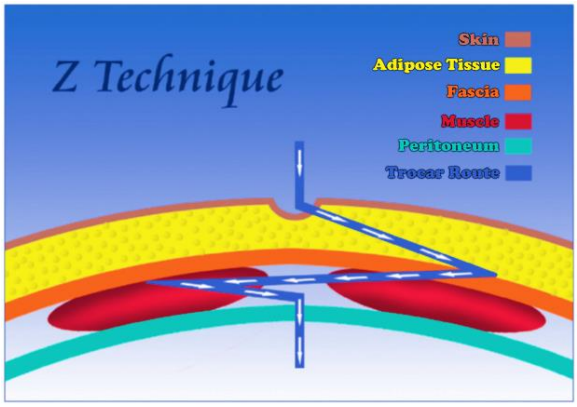

Figure 1. The schematic figure of the trocar entry into the abdominal cavity with the "Z-entry" technique.

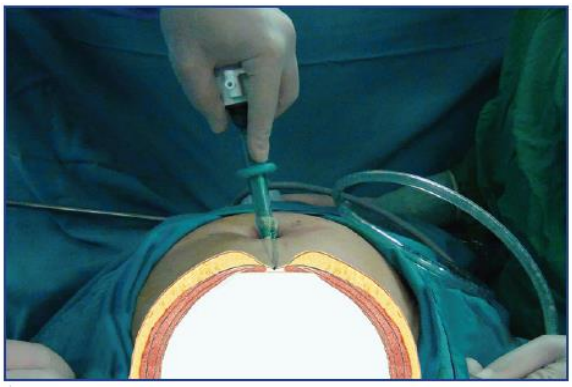

Figure 2.

[1] Hans-Christian Jacobaeus (1879–1937)

[2] Trocar Site Hernia (TSH)

[Downloaded from saremjrm.com on 2026-08-24]

[DOI: 10.52547/sjrm.5.4.212]

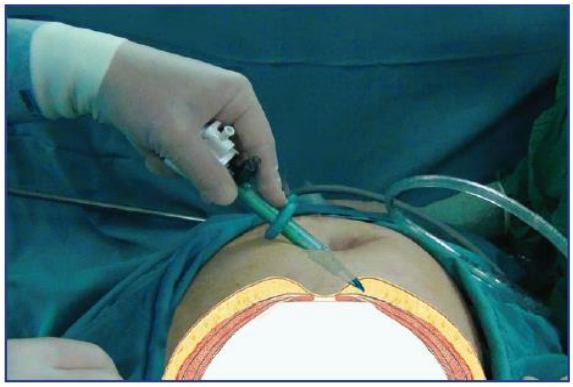

Figure 3.

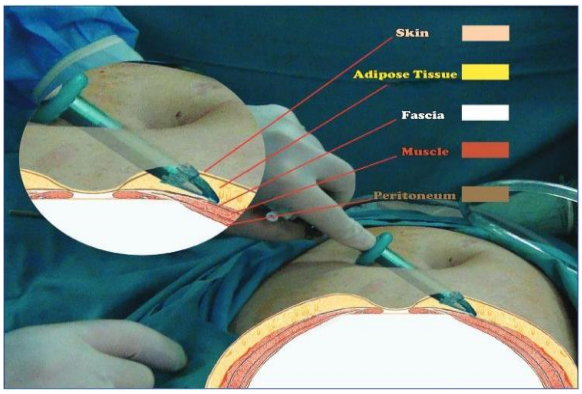

Figure 4.

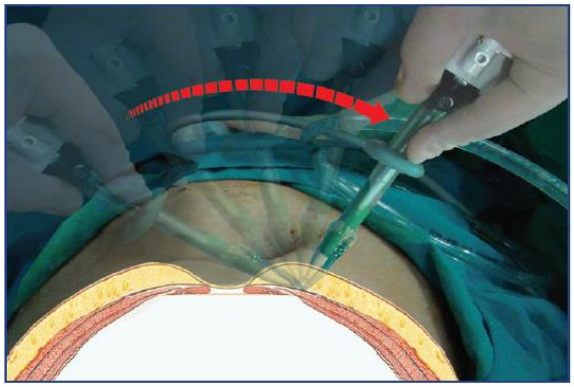

Figure 5.

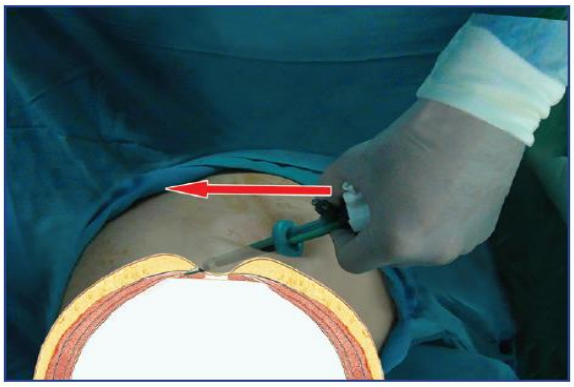

Figure 6.

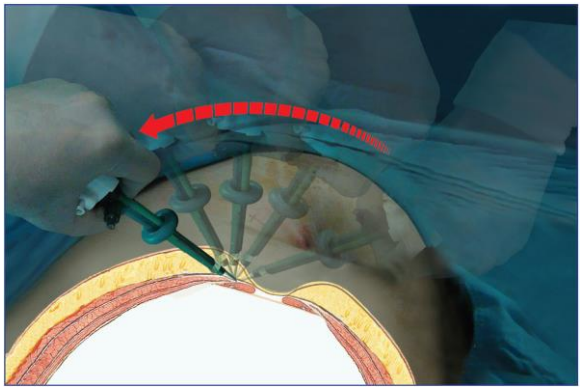

Figure 7.

Figure 8.

Figure 9.

The aim of this study was to evaluate the safety and possible complications of trocar insertion into the abdomen cavity in gynecologic laparoscopy surgery using the "Z-entry" technique.

[Downloaded from saremjrm.com on 2026-08-24]

[DOI: 10.52547/sjrm.5.4.212]

Methods

In this descriptive cross-sectional and retrospective study, all the medical records of patients who underwent laparoscopic surgery in Sarem Women's Hospital from March 2018 to March 2020 due to gynecological diseases were collected and statistically analyzed. In all laparoscopic procedures performed during this period, the "Z-entry" technique was used to insert the trocar into the abdominal cavity. In this study, 435 patients were studied and in addition to demographic data, the occurrence of complications including visceral injury, vascular injury, umbilical hernia, hematoma, massive hemorrhage, infection, and mortality due to trocar complications was investigated. In cases where the patient did not go to the hospital after surgery or his medical record information was incomplete, he was contacted by phone and if he mentioned complications such as swelling and deformity around the umbilicus, the patient was re-examined, and if there was a suspicion of an umbilical hernia, the patient was examined by ultrasound. The collected data were analyzed by SPSS software[3] and the results were reported in the form of descriptive statistics and frequency distribution tables.

Results

In this study, within two years (from March 2018 to March 2020), 435 patients underwent laparoscopic surgery and trocar insertion by the "Z-entry" method for various gynecological reasons. The minimum age of patients was 16 years and the maximum was 69 years, with a mean and standard deviation of 33.3.7±6.3 years. Among the patients, the lowest height and weight were 147 cm and 45 kg, respectively, while the highest height and weight were 180 cm and 110 kg, respectively, which the mean and standard deviation of them was 163.8±5.7 cm and 66.5±10.9 kg, respectively. The above descriptive statistics along with the body mass index (BMI) parameter are shown in Table 1.

Table 1. Demographic characteristics of the participants

Parameters (n=435)	Mean ± Standard Deviation	Minimum	Maximum
Age (year)	33.7 ± 6.3	16	69
Height (cm)	163.8 ± 5.7	147	180
Weight (kg)	66.5 ± 10.9	45	110
Body Mass Index, BMI (kg/m^2)	24.7 ± 3.9	16.5	38.9

[3] IBM SPSS, Version 25 (IBM Corp., Armonk, N.Y., USA)

The patients underwent laparoscopic surgery for a variety of reasons, the most common of which are shown in Figure 1. 140 (32.03%) of the cases had a history of previous abdominal surgery. In this two-year study, the rate of complications and problems due to trocar entry by Z method was very low in patients who underwent laparoscopic gynecological surgery, so that only one case of infection (0.2%), one case of hematoma (0.2%) , One case of trocar entry into arteries (0.2%) and only two cases (0.4%) of trocar entry into viscera were seen. During this time, no cases of umbilical hernia, extensive bleeding, and death from complications of trocar entry were found. Also, 14 patients had complained of deformity around the umbilicus, which during the examination in person and clinical examination, in 13 of them no case of umbilical hernia was seen and one suspected case underwent ultrasound in which no hernia was reported (Table 2).

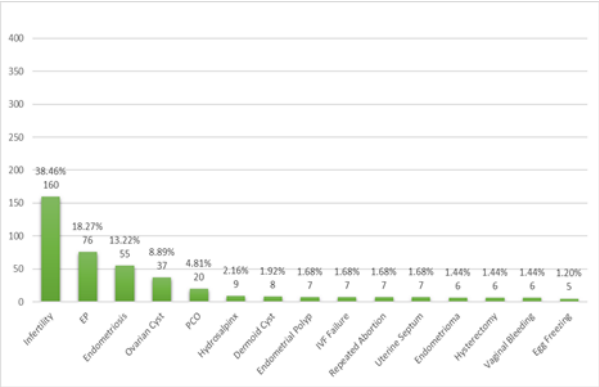

Table 2. The complications of trocar insertion by the “Z-entry” technique

Complication	Frequency	Percent
Visceral Injury		
Yes	2	0.46
No	433	99.54
Vascular Injury		
Yes	1	0.23
No	434	99.77
Hematoma		
Yes	1	0.23
No	434	99.77
Infection		
Yes	1	0.23
No	434	99.77
Umbilical Hernia		
Yes	0	0.00
No	434	100.00
Massive Hemorrhage		
Yes	0	0.00
No	434	100.00
Death (Due to trocar Insertion)		
Yes	0	0.00
No	434	100.00

[Downloaded from saremjrm.com on 2026-08-24]

[DOI: 10.52547/sjrm.5.4.212]

Discussion

Over the past two decades, rapid advances have been made in the techniques of laparoscopic surgery due to its high safety and low complications (11). Since half of the laparoscopic complications occur while entering the abdominal cavity, the technique of entry into the abdomen and its safety is very important (13). The closed technique (Veress Needle) and the open technique (Hasson Method) are the two most common classical methods in laparoscopy for entering the abdominal cavity (6,8,11). In the present study, a new technique was used to insert the trocar into the abdominal cavity, which is called the "Z-entry" method. In a study conducted in 2016, it was shown that the rate of complications and visceral damage in the open method was lower than in the closed method (14). On the other hand, the open technique has problems such as the long time it takes to enter the abdomen and the difficulty in the abdominal cavity insufflation due to gas leakage from around the inlet cannula (15). In the study by Taye et al., 1,500 cases of closed technique were compared with 1,500 cases of open technique, with one case reported death due to complications of the closed method (14). In this study, the overall rate of visceral injuries in the closed technique was reported to be 1.33% (14). In the present study, no cases of death due to trocar injury were found and the rate of visceral injury was about 0.4%. In various studies, the prevalence of trocar site hernia (TSH) has been reported to be 0.2 to 3.1% (10,16–19). However, in our study, no case of umbilical hernia was seen. Molloy et al. reported a rate of visceral injury during trocar entry between 0.4 and 1.1% (11,20), which this problem in the "Z-entry" method was similar to the lowest prevalence in other methods. The rate of vascular injury during trocar entry has been reported in various articles from 0.03 to 1.33% depending on the type of technique and the type of trocar device (21-23). In the present study, the vascular injury was occurred in only one case (0.2%). The incidence of abdominal wall hematoma after laparoscopic surgery is seen from 2 to 6.25% (24,25), while in the "Z-entry" technique, the hematoma was reported to be about 0.2%. In a study, Mayol et al. reported a rate of trocar site infection of 1.2% (25), which occurred in only one case (0.2%) in our study. On the other hand, in the present study, no cases of massive bleeding were seen.

Conclusion

Today, laparoscopic surgery is widely used in abdominal surgeries and gynecology. Various techniques are used to insert the trocar into the abdominal cavity, which can be associated with injuries and complications for the patient. This study showed that the entry of the trocar into the abdominal cavity with the "Z-entry" technique is associated with minimal complications and injuries and has higher advantages over other methods and can be used as a technique with greater safety.

Acknowledgments

The authors acknowledge the esteemed staff of Sarem Women's Hospital and Sarem Fertility and Infertility Research Center (SAFIR), especially Mrs. Maryam Naderi.

Ethics

All patient identity data in this study are confidential and secure. The study protocol was approved by the “Institutional Review Board (IRB)” of Sarem Fertility and Infertility Research Center.

Conflict of interests

There was no conflict of interest in this study.

Source of funding

This study has been financially supported by Sarem Fertility and Infertility Research Center (SAFIR).

Authors’ ORCID

AboTaleb Saremi:
https://orcid.org/0000-0003-4191-6624
Mohammad Reza Nateghi:
https://orcid.org/0000-0001-5754-0516

References

1. Hatzinger M, Häcker A, Langbein S, Kwon S, Hoang-Böhm J, Alken P. Hans-Christian Jacobaeus (1879–1937). Der Urol 2006 459 [Internet]. 2006 [cited 2021 Sep 23];45(9):1184–6. Available from: https://link.springer.com/article/10.1007/s00120-006-1069-8
2. Hatzinger M, Kwon ST, Langbein S, Kamp S, Häcker A, Alken P. Hans Christian Jacobaeus: Inventor of Human Laparoscopy and Thoracoscopy. https://home.liebertpub.com/end

[Downloaded from saremjrm.com on 2026-08-24]

[DOI: 10.52547/sjrm.5.4.212]

[Internet]. 2006 Dec 4 [cited 2021 Sep 23];20(11):848–50. Available from: https://www.liebertpub.com/doi/abs/10.1089/end.2006.20.848

3. Vilos GA, Ternamian A, Dempster J, Laberge PY, Vilos G, Lefebvre G, et al. Laparoscopic Entry: A Review of Techniques, Technologies, and Complications. J Obstet Gynaecol Canada [Internet]. 2007 May [cited 2020 Dec 24];29(5):433–47. Available from: https://pubmed.ncbi.nlm.nih.gov/17493376/
4. Chang WC, Huang SC, Sheu BC. Advances in Gynecological Laparoscopic Surgery. J Formos Med Assoc. 2010 Apr 1;109(4):245–7.
5. Günenç MZ, Yesildaglar N, Bingöl B, Önalan G, Tabak S, Gökmen B. The safety and efficacy of direct trocar insertion with elevation of the rectus sheath instead of the skin for pneumoperitoneum. Surg Laparosc Endosc Percutaneous Tech [Internet]. 2005 [cited 2020 Dec 24];15(2):80–1. Available from: https://pubmed.ncbi.nlm.nih.gov/15821619/
6. Hasson HM. A modified instrument and method for laparoscopy. Am J Obstet Gynecol [Internet]. 1971 Jul 15 [cited 2021 Sep 21];110(6):886–7. Available from: http://www.ajog.org/article/000293787190593X/fulltext
7. Semm K, Semm I. Safe insertion of trocars and the Veress needle using standard equipment and the 11 security steps. Gynaecol Endosc [Internet]. 1999 Dec 1 [cited 2020 Dec 24];8(6):339–47. Available from: http://doi.wiley.com/10.1046/j.1365-2508.1999.00333.x
8. Veress J. Neues Instrument zur Ausführung von Brust-oder Bauchpunktionen und Pneumothoraxbehandlung. DMW-Deutsche Medizinische Wochenschrift. 1938;64(41):1480–1.
9. Ahmad G, Baker J, Finnerty J, Phillips K, Watson A. Laparoscopic entry techniques. Cochrane Database Syst Rev [Internet]. 2019 Jan 18 [cited 2020 Dec 24];2019(1). Available from: /pmc/articles/PMC6353066/?report=abstract
10. Lajer H, Widecrantz S, Heisterberg L. Hernias in trocar ports following abdominal laparoscopy: A review. Acta Obstet Gynecol Scand [Internet]. 1997 Jan 1 [cited 2020 Dec 24];76(5):389–93. Available from: http://doi.wiley.com/10.3109/00016349709047816
11. Molloy D, Kaloo PD, Cooper M, Nguyen T V. Laparoscopic entry: A literature review and analysis of techniques and complications of primary port entry [Internet]. Vol. 42, Australian and New Zealand Journal of Obstetrics and Gynaecology. Royal Australian and New Zealand College of Obstetricians and Gynaecologists; 2002 [cited 2020 Dec 24]. p. 246–54. Available from: https://obgyn.onlinelibrary.wiley.com/doi/full/10.1111/j.0004-8666.2002.00246.x
12. Gadekar A, Rege J, Satia M, Hambarde S. Omental herniation through trocar site. Ann Afr Med [Internet]. 2012 Jul [cited 2020 Dec 24];11(3):191. Available from: http://www.annalsafrmed.org/text.asp?2012/11/3/191/96885
13. Mintz M. Risks and prophylaxis in laparoscopy: a survey of 100,000 cases. J Reprod Med. 1977;18(5):269–72.
14. Taye MK, Fazal SA, Pegu D, Saikia D. Open versus closed laparoscopy: yet an unresolved controversy. J Clin diagnostic Res JCDR. 2016;10(2):QC04.
15. Bonjer HJ, Hazebroek EJ, Kazemier G, Giuffrida MC, Meijer WS, Lance JF. Open versus closed establishment of pneumoperitoneum in laparoscopic surgery. Br J Surg [Internet]. 1997 May 1 [cited 2021 Sep 21];84(5):599–602. Available from: https://onlinelibrary.wiley.com/doi/full/10.1046/j.1365-2168.1997.d01-1355.x
16. Crocetti D, Sapienza P, Pedulla` G, De Toma G. Reducing the risk of trocar site hernias. Ann R Coll Surg Engl [Internet]. 2014 [cited 2020 Dec 24];96(7):558. Available from: https://www.ncbi.nlm.nih.gov/pmc/articles/PMC4473458/
17. Swank HA, Mulder IM, la Chapelle CF, Reitsma JB, Lange JF, Bemelman WA. Systematic review of trocar-site hernia. Br J Surg [Internet]. 2012 Jan 30 [cited 2021 Sep 23];99(3):315–23. Available from: https://academic.oup.com/bjs/article/99/3/315/6138733
18. Tonouchi H, Ohmori Y, Kobayashi M, Kusunoki M. Trocar Site Hernia. Arch Surg [Internet]. 2004 Nov 1 [cited 2021 Sep 23];139(11):1248–56. Available from: https://jamanetwork.com/journals/jamasurgery/fullarticle/397584
19. Nacef K, Chaouch MA, Chaouch A, Ben Khalifa M, Ghannouchi M, Boudokhane M. Trocar site post incisional hernia: About 19 cases. Pan Afr Med J [Internet]. 2018 [cited 2020 Dec 24];29. Available from: https://pubmed.ncbi.nlm.nih.gov/30061961/

[Downloaded from saremjrm.com on 2026-08-24]

[DOI: 10.52547/sjm.5.4.212]

20. Tian YF, Lin YS, Lu CL, Chia CC, Huang KF, Shih TY, et al. Major complications of operative gynecologic laparoscopy in Southern Taiwan: A follow-up study. J Minim Invasive Gynecol. 2007 May 1;14(3):284–92.
21. Fuller J, Ashar BS, Carey-Corrado J. Trocar-associated injuries and fatalities: An analysis of 1399 reports to the FDA. J Minim Invasive Gynecol [Internet]. 2005 Aug 1 [cited 2021 Sep 23];12(4):302–7. Available from: http://www.jmig.org/article/S1553465005002979/fulltext
22. Merlin TL, Hiller JE, Maddern GJ, Jamieson GG, Brown AR, Kolbe A. Systematic review of the safety and effectiveness of methods used to establish pneumoperitoneum in laparoscopic surgery. Br J Surg [Internet]. 2003 Jun 9 [cited 2021 Sep 23];90(6):668–79. Available from: https://academic.oup.com/bjs/article/90/6/668/6143325
23. Pring C. Aortic injury using the Hasson trocar: a case report and review of the literature. Ann R Coll Surg Engl [Internet]. 2007 Mar 1;89(2):3–5. Available from: http://openurl.ingenta.com/content/xref?genre=article&issn=0035-8843&volume=89&issue=2&spage=3
24. Bhattacharya S, Tate JJT, Davidson BR, Hobbs KEF. Abdominal wall Haematoma Complicating Laparoscopic Cholecystectomy. HPB Surg. 1994;7(4):291–6.
25. Mayol J, Garcia-Aguilar J, Ortiz-Oshiro E, De-Diego Carmona JA, Fernandez-Represa JA. Risks of the Minimal Access Approach for Laparoscopic Surgery: Multivariate Analysis of Morbidity Related to Umbilical Trocar Insertion.

[Downloaded from saremjrm.com on 2026-08-24]

[DOI: 10.52547/sjrm.5.4.212]