

Management of Acute Necrotizing Chorioamnionitis Associated with Umbilical Cord Panvasculitis: A Case Report


ARTICLE INFO

DOI: 1052547/sjrm.10.4.5

Article Type

Case Report

Authors

Leila Alijani¹, Hadis Mohammadian¹,
Maryam Sanaye Naderi^{1,2},
Mohammad Reza Nateghi^{1,2*} 

1- Sarem Gynecology, Obstetrics and Infertility Research Center, Sarem Women's Hospital, Iran University of Medical Science (IUMS), Tehran, Iran.
2- Sarem Cell Research Center (SCRC), Sarem Women's Hospital, Tehran, Iran.

*Corresponding Authors:

Mohammad Reza Nateghi; Sarem Gynecology, Obstetrics and Infertility Research Center, Sarem Women's Hospital, Iran University of Medical Sciences, Tehran, Iran.
Address: Sarem Women Hospital, Basij Square, Phase 3, Ekbatan Town, Tehran, Iran. Postal code: 1396956111, Phone: +98 (21) 44670888, Fax: +98 (21) 44670432.

ABSTRACT

Background and Objective: Chorioamnionitis is a serious infectious complication of pregnancy associated with significant maternal and fetal morbidity and mortality. Acute necrotizing chorioamnionitis, particularly when accompanied by umbilical cord panvasculitis, represents a severe inflammatory process indicating fetal inflammatory response. This report aims to describe the diagnostic and therapeutic challenges in managing a case of acute necrotizing chorioamnionitis with panvasculitis in a high-risk pregnancy.

Case Presentation: A 29-year-old pregnant woman (G2P0Ab1) at 24 weeks of gestation, with a history of cervical cerclage and recurrent genital tract infections, was admitted with abdominal pain and vaginal bleeding. Despite the absence of classical signs of intra-amniotic infection, preterm premature rupture of membranes occurred, followed by worsening symptoms, leading to an emergency cesarean section. Intraoperative findings suggested severe intrauterine infection. Microbiological cultures revealed *Enterobacter cloacae* complex resistant to initial empirical antibiotics. Histopathological examination of the placenta and umbilical cord confirmed acute necrotizing chorioamnionitis with panvasculitis. Following antibiotic modification based on antibiogram results, the patient showed clinical improvement and was discharged in good condition.

Conclusion: This case highlights the importance of close surveillance of high-risk pregnancies after cervical cerclage, awareness of atypical presentations of intra-amniotic infection, and the critical role of placental pathology and targeted antibiotic therapy. Early recognition and timely multidisciplinary management are essential to reduce adverse maternal and fetal outcomes.

Keywords: Acute necrotizing chorioamnionitis, Umbilical cord panvasculitis, High-risk pregnancy.

Received: 14 January 2026

Accepted: 14 February 2026

e Published: 21 February 2026

Article History

Introduction

Chorioamnionitis is a significant and potentially life-threatening infection during pregnancy, characterized by inflammation of the fetal membranes and amniotic fluid, most commonly resulting from the ascending spread of microorganisms from the lower genital tract [2,22]. This condition is associated with a substantial increase in maternal and fetal complications, including preterm birth, neonatal sepsis, intrauterine fetal demise, and both short- and long-term neonatal morbidities, and it remains a major challenge in maternal–fetal medicine [3,4].

The incidence of chorioamnionitis is higher in high-risk pregnancies, particularly in cases of preterm rupture of membranes (PROM), cervical insufficiency, and invasive interventions such as cervical cerclage. Although cerclage is recognized as an effective method for preventing preterm birth in women with cervical insufficiency, it may itself facilitate ascending infection and intrauterine inflammation, especially in the presence of recurrent infections or intra-amniotic sludge [5,6].

From a pathological perspective, chorioamnionitis is classified into several forms, among which acute necrotizing chorioamnionitis represents one of the most severe and least common subtypes. This entity is characterized by extensive tissue destruction, membrane necrosis, and a pronounced inflammatory response, and is generally associated with poorer outcomes compared with milder forms. In such cases, involvement of the umbilical cord vessels in the form of panvasculitis (funisitis) reflects activation of the fetal immune response and indicates the spread of infection from the intrauterine environment to the fetal circulation [7].

Umbilical cord panvasculitis is of particular clinical significance because it is associated with an increased risk of fetal sepsis, severe neonatal morbidity, neurological injuries such as intraventricular hemorrhage (IVH), and perinatal mortality. The coexistence of acute necrotizing chorioamnionitis and umbilical cord panvasculitis denotes an advanced and aggressive inflammatory process, necessitating prompt and precise decision-making regarding the timing and mode of pregnancy termination [8,9].

The clinical diagnosis of chorioamnionitis is not always straightforward, as classical signs such as maternal fever, uterine tenderness, or foul-smelling vaginal discharge may be absent or only partially manifest in some cases. Under these circumstances, definitive diagnosis is often established based on pathological examination of the placenta and umbilical cord, as well as microbiological culture results. This highlights the critical value of meticulous placental evaluation after delivery as an important diagnostic tool [10,11].

Furthermore, the rising prevalence of antibiotic-resistant Gram-negative bacteria, including the

Enterobacter cloacae complex, has introduced new challenges in the therapeutic management of chorioamnionitis. Antimicrobial resistance may lead to failure of initial empirical therapy, persistence of infection, prolonged hospitalization, and increased postpartum complications in the mother, underscoring the necessity of antibiogram-guided therapy and repeated reassessment of treatment strategies [12,13].

Given the importance of timely diagnosis, appropriate antibiotic selection, and rapid clinical decision-making in high-risk pregnancies complicated by PROM and a history of cerclage, reporting rare clinical cases can play a crucial role in enhancing clinical awareness and improving management approaches. In this article, we report and discuss the management of a case of acute necrotizing chorioamnionitis associated with umbilical cord panvasculitis that occurred at Sarem Subspecialty Hospital. This case underscores the necessity of close post-cerclage surveillance, attention to non-classical signs of infection, and the pivotal role of pathological and microbiological findings in guiding effective treatment.

Case Presentation

A 29-year-old pregnant woman, gravida 2, para 0, abortion 1, living 0 (G2P0Ab1L0), at 24 weeks of gestation, presented to and was admitted to the labor ward of Sarem Subspecialty Hospital with complaints of abdominal pain and vaginal bleeding. She had a history of one pregnancy loss at 20 weeks of gestation in her previous pregnancy due to cervical insufficiency. In the current pregnancy, following the diagnosis of a short cervix on ultrasonography at 18 to 19 weeks of gestation, a cervical cerclage had been performed outside our center by another physician.

After cerclage placement, the patient experienced recurrent genital tract infections and sonographic evidence of intra-amniotic sludge, for which she received several courses of antibiotic therapy, including cefixime and clindamycin. Despite these treatments, on 16/08/1404, she was readmitted because of worsening abdominal pain, vaginal bleeding, and a reduction in cervical length to approximately 6 mm.

At the time of admission, she exhibited no systemic signs of infection, including fever, uterine tenderness, or foul-smelling vaginal discharge. Given the gestational age and the consideration that the fetus was potentially viable, conservative management was initiated, including magnesium sulfate for neuroprotection and betamethasone to promote fetal lung maturation. However, approximately 7 to 8 hours after admission, spontaneous rupture of membranes occurred, with clear leakage of amniotic fluid observed clinically. Owing to the presence of vaginal bleeding, the AmniSure test yielded a false-negative result, although overt clinical evidence of membrane rupture was present. Concurrently, uterine

contractions intensified, and vaginal examination revealed cervical dilatation of 3 cm with approximately 40 to 50% effacement.

In view of the gestational age, breech presentation, rupture of membranes, and following comprehensive consultations with the family, the forensic medicine authority, and the neonatal intensive care unit (NICU) team, an emergency cesarean section was undertaken with the aim of reducing the risk of fetal neurological complications, including intraventricular hemorrhage (IVH). During surgery, after uterine incision and rupture of the membranes, a markedly foul odor of the amniotic fluid was noted, strongly suggestive of severe intrauterine infection. A sample of amniotic fluid was obtained for microbiological culture, and intraoperative clindamycin was administered.

The neonate was delivered with Apgar scores of zero at both the first and fifth minutes. The umbilical cord appeared pale, and petechial lesions were observed on the fetal body (Figure 1). The fetus was referred for genetic evaluation and autopsy, and the placenta was submitted for pathological examination (Figure 2).

Postoperatively, due to strong clinical suspicion of severe infection, an urgent internal medicine consultation was requested, and broad-spectrum antibiotic therapy with vancomycin and piperacillin–tazobactam was initiated. Prophylactic enoxaparin was also prescribed to prevent thromboembolic complications, and blood cultures were obtained. From the first postoperative day, the patient developed fever, accompanied by elevated inflammatory markers, including C-reactive protein (CRP).

Cultures of both amniotic fluid and blood yielded growth of *Enterobacter cloacae* complex, demonstrating high-level resistance to the initial empirical antibiotics. Based on the antibiogram results, the antibiotic regimen was modified to cefixime and trimethoprim–sulfamethoxazole. Despite persistent fever and elevated CRP levels, the patient did not appear clinically ill or toxic during serial examinations. On the fourth postoperative day, malodorous discharge was noted from the surgical wound. The wound was opened and irrigated, and a sample of the discharge was sent for culture, which again grew *Enterobacter cloacae* complex.

Approximately three days after initiation of the revised antibiotic regimen, the patient's fever resolved and inflammatory markers showed a declining trend. Ultimately, after completing the treatment course and with a satisfactory general condition, the patient was discharged from the hospital.

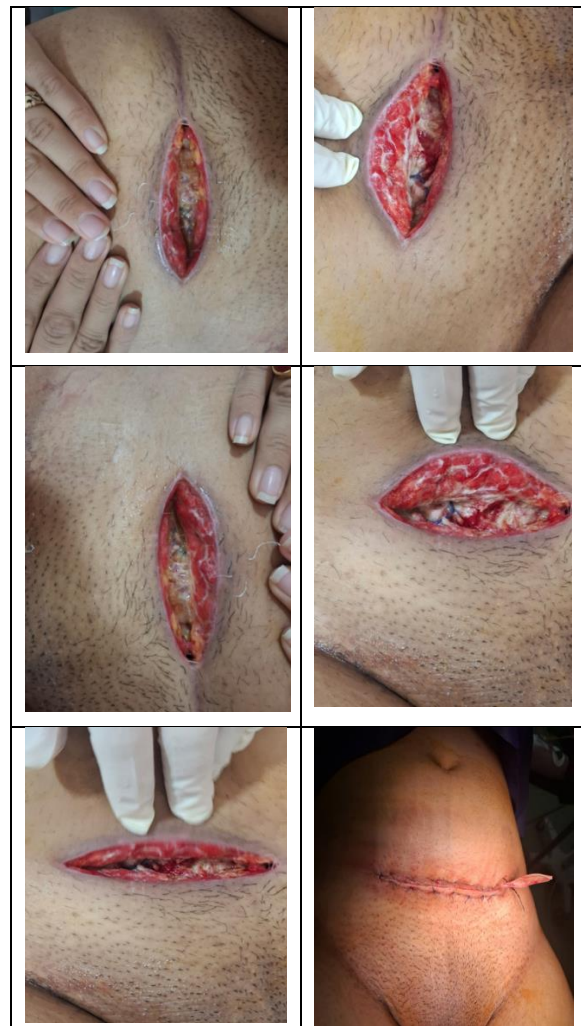


Figure 1. Macroscopic and microscopic appearance of the placenta and umbilical cord in acute necrotizing. Chorioamnionitis

PATHOLOGY REPORT

CLINICAL DATA: GA: 24-25w, PROM, foul amniotic fluid and meconium passage

SPECIMEN: Placenta, delivery

MACROSCOPIC DESCRIPTION:

Specimen received in formalin and consists of a singleton placenta. The white cord measures 21cm in length by 1cm in maximal diameter. It inserts velamentously at the disc and contains three vessels on cut section. No true knots, edema or other lesions are noted. The turbid green fetal membranes attach normally at the disc. The placental weighs 367gr and measured 15x11x3cm. The fetal surface is unremarkable, and no thrombi in the chorionic plate vessels are grossly identified. The maternal surface is intact without disruption. Serial sections through the placental disc at 1cm intervals reveals spongy dark red parenchyma with no lesions.

BLOCK DESCRIPTION:

RSS in 1 block.

MICROSCOPIC DESCRIPTION:

Please see the diagnosis.

DIAGNOSIS: Placenta, delivery:

- Umbilical cord: Umbilical panvasculitis (stage 2, intermediate), mild-moderate inflammation (grade 1) [fetal inflammatory response]
- Fetal membrane: Necrotizing chorioamnionitis (stage 3, advanced) severe inflammation (grade 2) [maternal inflammatory response]
- Placental disc: No significant pathologic changes.

Figure 2. Pathological report of the placenta and umbilical cord in acute necrotizing chorioamnionitis associated with umbilical cord panvasculitis.

Discussion

The purpose of this case report is to highlight the diagnostic and therapeutic challenges of acute necrotizing chorioamnionitis associated with umbilical cord panvasculitis in a high-risk pregnancy and to emphasize the importance of close surveillance following cervical cerclage. This case is particularly noteworthy because, despite the absence of classic clinical signs of intrauterine infection at the time of admission, the patient developed a severe and advanced inflammatory process that ultimately resulted in an adverse fetal outcome and significant maternal infectious complications. Furthermore, the identification of a Gram-negative pathogen resistant to initial empirical therapy underscores the critical role of targeted, antibiogram-guided antibiotic management in such patients.

Classically, chorioamnionitis is characterized by maternal fever, uterine tenderness, maternal or fetal tachycardia, and foul-smelling vaginal discharge [14]. However, several studies have demonstrated that in a substantial proportion of cases, particularly at earlier gestational ages, these signs may be absent or only partially present [15,16]. The findings of the present case are consistent with previous reports indicating that subclinical chorioamnionitis may progress without overt clinical manifestations and may only be diagnosed through pathological examination of the placenta and umbilical cord.

Previous studies have identified preterm rupture of membranes and cervical shortening as major risk factors for chorioamnionitis. In addition, although cervical cerclage plays a well-established role in the prevention of preterm birth, it may increase the risk of ascending infection, particularly in patients with a history of recurrent genital tract infections or intra-amniotic sludge [17,18]. In the present report, the history of cerclage, recurrent infections prior to admission, and early PROM are all in line with earlier findings and collectively highlight the cumulative effect of multiple risk factors in the development of severe intrauterine infection.

From a pathological standpoint, acute necrotizing chorioamnionitis represents one of the most severe forms of intrauterine inflammation, characterized by extensive tissue destruction and membrane necrosis. The presence of umbilical cord panvasculitis reflects a fetal inflammatory response and has been strongly associated with an increased risk of intrauterine fetal demise, fetal sepsis, and neonatal neurological injury [19,20]. The pathological findings in this case, demonstrating the coexistence of necrotizing chorioamnionitis and panvasculitis, are consistent with similar reports and confirm the high severity of the inflammatory process.

From a microbiological perspective, although *Escherichia coli* and Group B *Streptococcus* are among the most commonly reported pathogens in chorioamnionitis, recent data indicate a growing

prevalence of opportunistic and antibiotic-resistant Gram-negative organisms, including the *Enterobacter cloacae* complex [21]. These pathogens frequently exhibit poor responses to standard empirical regimens and are associated with prolonged hospitalization, persistent fever, and increased postpartum complications. In the present case, high-level resistance of the causative organism to initial antibiotics led to persistent fever and elevated inflammatory markers, with clinical improvement observed only after modification of therapy based on antibiogram results, a finding consistent with previous reports.

Regarding therapeutic decision-making, multiple studies have emphasized the importance of timely delivery in cases of suspected intrauterine infection, particularly in the presence of PROM and progressive clinical findings. In this case, the decision to perform an emergency cesarean section was made with the aim of reducing the risk of fetal neurological complications, including intraventricular hemorrhage, illustrating the necessity of a rapid, multidisciplinary approach in such complex clinical scenarios. Overall, the findings of this report are in agreement with existing literature, demonstrating that severe chorioamnionitis may develop even in the absence of classic clinical signs and may be associated with serious maternal and fetal consequences. This case underscores the importance of close monitoring of high-risk patients after cervical cerclage, attention to nonspecific signs of infection, routine submission of the placenta for pathological examination, and early use of antibiogram-guided therapy in the management of resistant infections.

Conclusion

This case report demonstrates that severe chorioamnionitis can rapidly progress in high-risk pregnancies, even in the absence of classic signs of intrauterine infection, and may result in serious maternal and fetal outcomes. The coexistence of acute necrotizing chorioamnionitis and umbilical cord panvasculitis reflects an advanced inflammatory response and highlights the importance of prompt decision-making and a multidisciplinary approach. Moreover, the increasing prevalence of antibiotic-resistant pathogens emphasizes the necessity of timely use of antibiogram results and reassessment of empirical therapies. Close surveillance following cervical cerclage, careful attention to nonspecific indicators of infection, and routine pathological evaluation of the placenta may play a pivotal role in improving clinical outcomes and informing the development of more effective management protocols.

Ethical Issue

In conducting this research, all ethical principles in medical and biological research were observed in accordance with the Declaration of Helsinki, and the

rights, dignity, and confidentiality of the participants were protected.

Conflict of Interests

There was no conflict of interest in this study.

Source of Funding

The costs of this project were funded by the Sarem Gynecology, Obstetrics and Infertility Research Center.

References

1. Jung E, Romero R, Suksai M, Gotsch F, Chaemsathong P, Erez O et al. Clinical chorioamnionitis at term: definition, pathogenesis, microbiology, diagnosis, and treatment. *Am J Obstet Gynecol* 2024;230:S807-s40.
2. Romero R, Pacora P, Kusanovic JP, Jung E, Panaitescu B, Maymon E et al. Clinical chorioamnionitis at term X: microbiology, clinical signs, placental pathology, and neonatal bacteremia - implications for clinical care. *Journal of perinatal medicine* 2021;49:275-98.
3. Zaki D, Balayla J, Beltempo M, Gazil G, Nuyt AM, Boucoiran I. Interaction of chorioamnionitis at term with maternal, fetal and obstetrical factors as predictors of neonatal mortality: a population-based cohort study. *BMC pregnancy and childbirth* 2020;20:454.
4. Boskabadi H ,Zakerihamidi M. Evaluation of Maternal Risk Factors, Delivery, and Neonatal Outcomes of Premature Rupture of Membrane: A Systematic Review Study. *Journal of Pediatrics Review* 2019;7:77-88.
5. Zullo F, Di Mascio D. Management of cervical cerclage after preterm premature rupture of membranes: an argument for removal. *American journal of obstetrics & gynecology MF* 2025;7:101570.
6. van Dijk CE, Breuking SH, Jansen S, Limpens JCEJM, Kazemier BM, Pajkrt E. Perioperative complications of a transvaginal cervical cerclage in singleton pregnancies: a systematic review and meta-analysis. *American Journal of Obstetrics and Gynecology* 2023;228:521-34.e19.
7. Cappelletti M, Presicce P, Kallapur S. Immunobiology of Acute Chorioamnionitis. *Frontiers in Immunology* 2020;11:649.
8. Ducey J, Owen A, Coombs R, Cohen M. Vasculitis as part of the fetal response to acute chorioamnionitis likely plays a role in the development of necrotizing enterocolitis and spontaneous intestinal perforation in premature neonates. *European journal of pediatric surgery : official journal of Austrian Association of Pediatric Surgery ... [et al] = Zeitschrift fur Kinderchirurgie* 2015;25:284-91.
9. Villamor-Martinez E, Fumagalli M, Mohammed Rahim O, Passera S, Cavallaro G, Degraeuwe P et al. Chorioamnionitis Is a Risk Factor for Intraventricular Hemorrhage in Preterm Infants: A Systematic Review and Meta-Analysis. *Frontiers in physiology* 2018;9:1253.
10. Tita AT, Andrews WW. Diagnosis and management of clinical chorioamnionitis. *Clinics in perinatology* 2010;37:339-54.
11. Carter SWD, Neubronner S, Su LL, Dashraath P, Mattar C, Illanes SE et al. Chorioamnionitis: An Update on Diagnostic Evaluation. *Biomedicines* 2023;11:2922.
12. Intra J, Carcione D, Sala RM, Siracusa C, Brambilla P, Leoni V. Antimicrobial Resistance Patterns of *Enterobacter cloacae* and *Klebsiella aerogenes* Strains Isolated from Clinical Specimens: A Twenty-Year Surveillance Study. *Antibiotics (Basel, Switzerland)* 2023;12:
13. Rallis D, Giapros V, Serbis A, Kosmeri C, Baltogianni M. Fighting Antimicrobial Resistance in Neonatal Intensive Care Units: Rational Use of Antibiotics in Neonatal Sepsis. *Antibiotics* 2023;12:508.
14. Derese TN, Wondafrash MD, Teka AM, Mideksa HS, Mario LD, Hundie TG et al. Chorioamnionitis and its associated factors among women admitted to the maternity unit of Public Hospitals in Addis Ababa, Ethiopia. *PLOS global public health* 2025;5:e0004467.
15. Algerian K. Chorioamnionitis: Establishing a correlation between clinical and histological diagnosis. *Indian Journal of Pathology and Microbiology* 2020;63:44-48.
16. Kay VR, Liang I, Turvey S, Vandersluis A, Norgaard A, Twiss J et al. Characteristics and Management of Chorioamnionitis at an Academic Centre in Ontario Before and After Implementation of an Order Set. *Journal of Obstetrics and Gynaecology Canada* 2024;46:102430.

17. van der Krogt L, Malligiannis Ntalianis K, Resta C, Suff N, Shennan A, Story L. The role of cervical cerclage in preventing preterm birth. *European Journal of Obstetrics & Gynecology and Reproductive Biology* 2025;311:114060.
18. Strong TH, Jr. Amnioinfusion with preterm, premature rupture of membranes. *Clinics in perinatology* 1992;19:399-409.
19. Redline RW, Ravishankar S, Bagby CM, Saab ST, Zarei S. Four major patterns of placental injury: a stepwise guide for understanding and implementing the 2016 Amsterdam consensus. *Modern Pathology* 2021;34:1074-92.
20. Kim CJ, Romero R, Chaemsathong P, Chaiyasit N, Yoon BH, Kim YM. Acute chorioamnionitis and funisitis: definition, pathologic features, and clinical significance. *Am J Obstet Gynecol* 2015;213:S29-52.
21. Miselli F, Cuoghi Costantini R, Creti R, Sforza F, Fanaro S, Ciccio M et al. *Escherichia coli* Is Overtaking Group B Streptococcus in Early-Onset Neonatal Sepsis. *Microorganisms* 2022;10.
22. Jung E, Romero R, Suksai M, Gotsch F, Chaemsathong P, Erez O et al. Clinical chorioamnionitis at term: definition, pathogenesis, microbiology, diagnosis, and treatment. *American Journal of Obstetrics & Gynecology* 2024;230:S807-S40.