

An Overview of Harlequin Ichthyosis

ARTICLE INFO

DOI: 1052547/sjrm.10.4.3

Article Type

Review article

Authors

Hadis Mohammadian¹, Mohammad Reza Nateghi^{1,2} 

1- Sarem Gynecology, Obstetrics and Infertility Research Center, Sarem Women's Hospital, Iran University of Medical Science (IUMS), Tehran, Iran.
2- Sarem Cell Research Center (SCRC),

*Corresponding Authors:

Mohammad Reza Nateghi; Sarem Gynecology, Obstetrics and Infertility Research Center, Sarem Women's Hospital, Iran University of Medical Sciences, Tehran, Iran.

Address: Sarem Women Hospital, Basij Square, Phase 3, Ekbatan Town, Tehran, Iran. Postal code: 1396956111, Phone: +98 (21) 44670888, Fax: +98 (21) 44670432.

ABSTRACT

Harlequin Ichthyosis is a very rare and severe genetic disorder of the group of congenital keratinization disorders that is inherited as an autosomal recessive trait and is caused by a mutation in the ABCA12 gene. This mutation causes a defect in epidermal lipid transport and, as a result, disruption of the skin lipid barrier. Affected infants are born with very thick, cracked skin and armor-like horny plates, with ectropion, eclampsia and limited limb movement, and are at high risk of dehydration, infection and temperature disorders due to damage to the skin barrier. The diagnosis of the disease is mainly clinical and is confirmed by genetic studies to identify ABCA12 mutations. In carrier families, prenatal diagnosis is possible with amniocentesis or placental villi sampling. Supportive care in the neonatal intensive care unit (NICU), including fluid balance, infection prevention, use of emollients, and systemic retinoid therapy, has improved survival and quality of life.

Despite the lack of a definitive cure, recent advances in molecular genetics and neonatal care have provided new hope for these patients. A detailed understanding of the relationship between genotype and phenotype will pave the way for the development of targeted and gene-based therapies in the future

Keywords: Harlequin Ichthyosis; ABCA gene; Autosomal Recessive Congenital Ichthyosis – (ARCI) ; Systemic Retinoids; Skin Barrier; Genetic Mutation; Prenatal Diagnosis.

Received: 09 December 2025

Accepted: 04 February 2026

e Published: 10 February 2026

Article History

Introduction

Harlequin ichthyosis (HI) is a very rare and severe disorder of skin keratinization that is inherited in an autosomal recessive manner and is associated with severe thickening of the stratum corneum and breakdown of the skin barrier in newborns [1].

Although survival in these patients was very poor in the past, advances in neonatal care, infection management, and the introduction of early systemic retinoids have led to a significant improvement in the prognosis in some patients [1].

The aim of this review is to provide a comprehensive and up-to-date review of the definition, etiology, clinical manifestations, diagnosis, treatment, and prognosis of harlequin ichthyosis. It is hoped that this review can serve as a starting point for researchers and related specialists such as dermatologists and geneticists to expand the existing knowledge to improve the diagnosis, care, and quality of life of sufferers.

Definition

Harlequin ichthyosis is a very rare and severe genetic disorder of the group of disorders of keratinization of the skin (ARCI) that is associated with very early onset and an extremely distinctive skin appearance in infants. The main cause of the disease is double mutations (homozygous or compound heterozygous) in the ABCA12 gene. This gene is responsible for the production of a lipid carrier protein of the ATP-Binding Cassette family that is required for the transport of lipids into the stratum corneum and the formation of the lipid barrier. Most severe cases (classic HI) are associated with termination or deletion mutations in ABCA12. Loss-of-function mutations in the ABCA12 gene are known to be the main cause of this disease; this gene is responsible for the transport and transfer of lipids in the lamellar granules of epidermal keratinocytes and its defect leads to disruption of the structure and function of the skin lipid barrier [2].

Etiology:

From a dermatological perspective

From a dermatological perspective, the central point is that HI represents a structural-functional breakdown of the skin barrier rather than simply a “keratinization problem.” Reduction or absence of ABCA12 results in reduced lipid load and abnormalities in the lamellar morphology of granules; as a result, corneocyte adhesion and the microstructure of the stratum corneum are disrupted, resulting in the formation of thick, scaly plates. Histological studies and genetic models have shown that this disorder not only alters lipid composition but also alters the process of keratinocyte differentiation, which explains symptoms such as eyelid ectropion, lip extroversion, and limb movement restriction. This perspective contributes to

a better understanding of the relationship between the type of mutation (truncating vs missense) and clinical severity [2].

From a neonatological perspective

For neonates, the failure to form a lipid barrier leads to rapid systemic consequences. These include rapid dehydration, severe electrolyte loss, increased risk of secondary infection (microbial penetration through a compromised barrier), impaired core temperature regulation, and in some cases respiratory restriction due to cortical rigidity of the face and chest. From a neonatological perspective, this means that the molecular etiology (lack of ABCA12 function) has a direct clinical translation that requires immediate care in the NICU to maintain hydration, control temperature, prevent and treat infection, and provide appropriate nutritional and respiratory support; thus, the molecular etiology directly determines clinical management. Early use of systemic retinoids has helped to break up corneal plaques in some cases and facilitate survival, although the treatment decision should be made according to the infant's systemic status and the type of mutation [5].

From a genetic perspective

From a molecular genetic perspective, HI is an autosomal recessive disease. Carrier couples each carry one defective allele and have a 25% risk of having an affected child. The spectrum of ABCA12 mutations is broad and can include terminating mutations, deletions, and single mutations. Data show that truncating mutations in both alleles are often associated with the classic and severe HI phenotype; Compound-Heterozygous or Missense-Rich states may produce milder phenotypes (discordance between genotype and phenotype). Molecular diagnosis (Sequencing/NGS Panel/WES) is essential to confirm the diagnosis and provide genetic counseling, as well as for prenatal diagnosis or early fetal diagnosis in high-risk pregnancies. Recent reports have also described cases of attenuated and phenotypic segregation, highlighting the importance of accurate genotypic analysis [4].

Clinical manifestations:

The newborn is covered with thick, septate or “armored” plaques with deep fissures between the horny plates (Figure 1) [1].

Ectropion (inverted eyelids), eclabium (pouting lips), contracture deformities of the limbs, and impaired breathing/swallowing may be seen, indicating that these infants have severe respiratory, feeding, and thermoregulation disorders, and are at risk of severe infections and dehydration; a point of great importance from a neonatological and intensive care perspective (Figure 2) [1].

Due to the defective skin barrier, these infants are also at high risk of dehydration, impaired thermoregulation, and secondary infections [3]. The skin of the palms and soles is often severely thickened in HI, with swelling and limitation of movement of the extremities. This manifestation is an important part of the disease phenotype. In patients who have passed the neonatal period, the clinical pattern may change from armor plates to a state with thicker scales and widespread erythema. This picture shows the condition after passing through the acute phase (Figure 3). The images of the extremities (arms, legs) with thick plaques, swelling and sometimes contractures show that the effect of HI is not only cutaneous, but that the disease also has destructive functional effects. Figure 4 is a schematic or microscopic comparison of lipid transport in healthy and HI-affected skin, showing that in healthy skin, lamellar granules deliver lipid content to the intercellular space, but in HI due to ABCA12 deficiency this process is impaired [2].

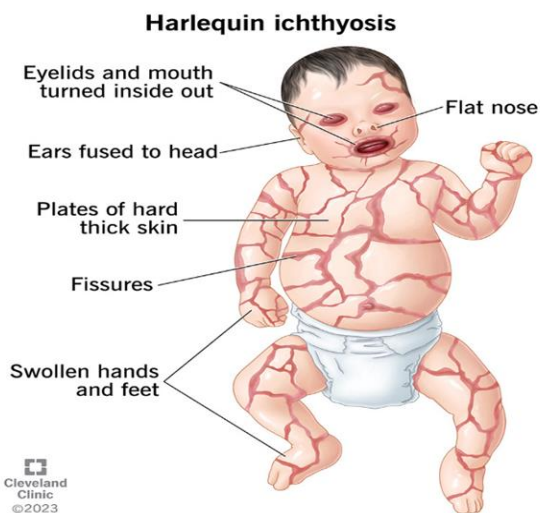


Figure 1. Schematic view of the clown embryo manifestation.

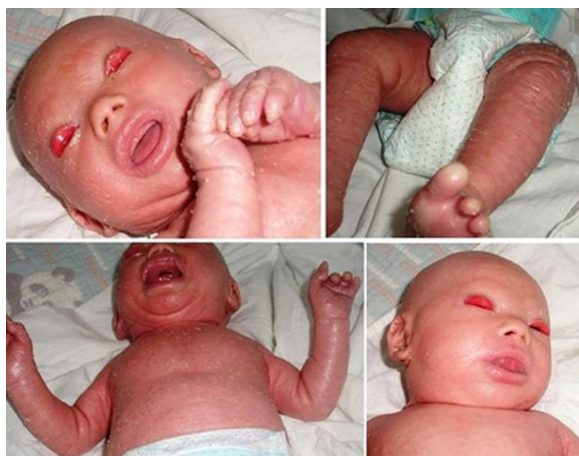

Figure 2. Clinical presentation in Harlequin ichthyosis

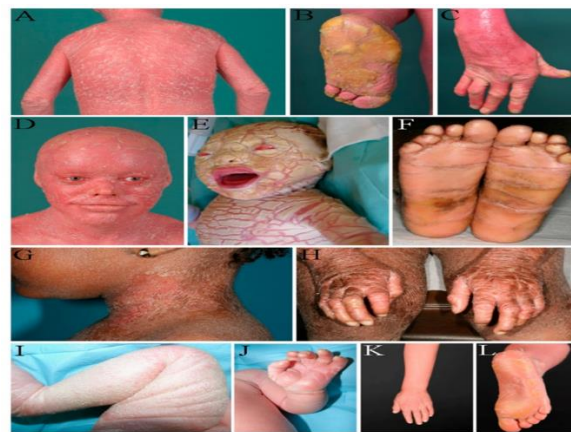

Figure 3. Skin complications and organ involvement in harlequin ichthyosis

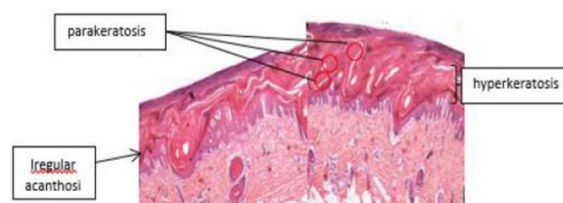


Figure 4. Microscopic view of the skin in harlequin ichthyosis

Diagnosis:

The initial diagnosis is usually clinical and at birth; molecular confirmation is by sequencing or analysis of ABCA12 mutations [1]. HI is often seen in newborns with a very characteristic and severe clinical picture (thick and armored plaques, deep gaps between the horny plates, ectropion, eclabium, limb limitation) for which clinical examination is sufficient to suggest the diagnosis. Initial investigations should be performed quickly because the condition of the newborn may be critical (dehydration, infection, respiratory distress) [6]. Sometimes mRNA sampling from hair follicles or epidermal cells has also been used for genetic analysis [6]. In high-risk pregnancies, prenatal diagnostic methods (targeted ultrasonography and fetal genetic testing) can help with early diagnosis [7]. In high-risk pregnancies (e.g., carriers or a history of affected children), 2D or 3D ultrasound can be used in the second trimester to detect physical signs such as fetal skin lesions, preocular cysts, hypoechoic amniotic fluid, and organ restriction [5]. Confirmation of the diagnosis of HI is achieved by genetic testing for mutations in the ABCA12 gene; this is the most accurate way to diagnose [8]. Early diagnosis is also possible by amniocentesis or chorionic villus sampling (CVS) followed by genetic testing for ABCA12 mutations [9]. Although skin biopsy alone is usually not sufficient to diagnose HI, histological findings include severe thickening of the stratum corneum (hyperkeratosis), parakeratosis, and thickening of the granular layer [8].

Differential diagnoses (Table 1):

In diagnosing HI, it is essential to consider other similar conditions to make an appropriate distinction. Some of the most important differential diagnoses include:

- Lamellar Ichthyosis and Congenital Ichthyosiform Erythroderma (both ARCI group) are usually associated with collodion membrane or erythroderma at birth, but do not have the severity and appearance of thick armored plates of HI [10].
- Restrictive Dermopathy; a rare disorder with short survival and severe skin features that may be confused with HI [10].
- Netherton Syndrome; includes ichthyosis with hair fragility and immunodeficiency, thus differentiating it from HI [11].
- Sjögren–Larsson Syndrome; a combination of ichthyosis, neurologic confusion, and other metabolic disorders and may show extensive scaling but does not have the HI phenotype [8].
- Gaucher Disease; the severe form may present as a “collodion baby” but with different systemic features [12].

Table 1. Differential diagnoses of harlequin ichthyosis and pregnancy history, the initial clinical diagnosis was intra-abdominal hemorrhage secondary to a ruptured ectopic pregnancy.

Disease	Main features	Key diagnostic findings	Differentiation from HI
Lamellar Ichthyosis (LI)	Newborn with collodion membrane, thin brown-gray scales	Mutation in the ALOX12B or TGM1 gene	No thick armored plaques and deep fissures
Congenital Ichthyosiform Erythroderma (CIE)	Diffuse desquamation with milder erythroderma	Mutation in the ABCA12, NIPAL4, CERS3 genes.	No severe ectropion and restricted movement
Restrictive Dermopathy (RD)	Very tight and thin skin, severe limitation of movement	Mutation in the ZMPSTE24 gene	Thin, stretched skin versus thick skin in HI
Netherton Syndrome (NS)	Diffuse desquamation, brittle hair, increased IgE	Defect in the SPINK5 gene	Presence of bamboo hair and allergies are distinctive
Sjögren–Larsson Syndrome (SLS)	Ichthyosis with mental retardation and spasticity	Mutation in the ALDH3A2 gene	Neurological signs are absent in HI
Gaucher Disease Type 2 (Neonatal Form)	Thickened, collodion-like skin, with neurological deficit	Decreased glucocerebrosidase	Significant systemic and neurological dysfunction

Treatment and management:

Definitive genetic therapy is not yet widely available in practice; supportive care in the NICU, including fluid and electrolyte maintenance, temperature control, skin care (emollients, protective dressings), and infection control, is essential [1]. Early introduction of systemic retinoids, such as acitretin, in recent decades has been associated with improved survival in some patients, although response and risks depend on the type of mutation and clinical condition [1].

Conclusion:

Harlequin ichthyosis (clown fetus) is one of the rarest and most severe genetic skin disorders caused by mutations in the ABCA12 gene, leading to a serious defect in the formation of the skin lipid barrier. This molecular defect causes a set of severe clinical symptoms, including extensive skin thickening, the formation of armor-plated plaques, ectropion, eclabium, limb movement restriction, and an increased risk of infection and dehydration.

Despite the very serious nature of the disease, recent advances in neonatal care, genetic diagnosis, and systemic retinoid treatments have significantly increased the survival and quality of life of patients. Accurate identification of the type of ABCA12 gene mutations and their relationship to the clinical phenotype plays a significant role in improving treatment strategies and genetic counseling.

Early diagnosis, whether through clinical and genetic screening after birth or prenatal diagnosis in high-risk families, is of particular importance in reducing mortality and preventing new cases. Given the complex nature of this disease, multidisciplinary collaboration between dermatologists, neonatologists, geneticists, and critical care specialists is essential to provide effective supportive care and open new avenues of research for gene and targeted therapies. The future of managing these patients will depend on the integration of molecular knowledge, meticulous clinical care, and the development of new technologies in genetics and pharmacology.

Ethical Issue

This article is a review and does not include ethical considerations.

Conflict of Interests

There was no conflict of interest in this study.

Source of Funding

The costs of this project were funded by the Sarem Gynecology, Obstetrics and Infertility Research Center.

References

1. Rajpopat S, Moss C, Mellerio J, Vahlquist A, Gånemo A, Hellstrom-Pigg M, Ilchyshyn A, Burrows N, Lestringant G, Taylor A, Kennedy C, Paige D, Harper J, Glover M, Fleckman P, Everman D, Fouani M, Kayserili H, Purvis D, Hobson E, Chu C, Mein C, Kelsell D, O'Toole E. Harlequin ichthyosis: a review of clinical and molecular findings in 45 cases. *Arch Dermatol*. 2011 Jun;147(6):681-6. doi: 10.1001/archdermatol.2011.9. Epub 2011 Feb 21. PMID: 21339420.
2. Akiyama M. ABCA12 mutations and autosomal recessive congenital ichthyosis: a review of genotype/phenotype correlations and of pathogenetic concepts. *Hum Mutat*. 2010 Oct;31(10):1090-6. doi: 10.1002/humu.21326. PMID: 20672373.
3. Elkhatib AM, Omar M. Ichthyosis Fetalis. 2023 Aug 7. In: StatPearls [Internet]. Treasure Island (FL): StatPearls Publishing; 2025 Jan-. PMID: 32809327.
4. Hotz, Alrun, Julia Kopp, Emmanuelle Bourrat, Vinzenz Oji, Kira Süßmuth, Katalin Komlosi, Bakar Bouadjar, Iliana Tantcheva-Poór, Maritta Hellström Pigg, Regina C. Betz, and et al. 2023. "Mutational Spectrum of the ABCA12 Gene and Genotype-Phenotype Correlation in a Cohort of 64 Patients with Autosomal Recessive Congenital Ichthyosis" *Genes* 14, no. 3: 717. <https://doi.org/10.3390/genes14030717>
5. Tsivilika M, Kavvadas D, Karachrysafti S, Sioga A, Papamitsou T. Management of Harlequin Ichthyosis: A Brief Review of the Recent Literature. *Children (Basel)*. 2022 Jun 15;9(6):893. doi: 10.3390/children9060893. PMID: 35740830; PMCID: PMC9221756.
6. Fnu Nutan, Dirk M Elston, Harlequin Ichthyosis Workup/Aug 08, 2025/ https://www.medscape.com/?_gl=1*pn9fg4*_gcl_a_u*NzQ1MTE3MTMzLjE3NjE2NDMwNjU.
7. Liu J, Zhang X, Wang W, Lan X, Dong M, Yan K, Lei Y, Chen P, Yang M, Shan Q, Jin C. Case Report: Prenatal Diagnosis of a Fetus With Harlequin Ichthyosis Identifies Novel Compound Heterozygous Variants: A Case Report. *Front Genet*. 2021 Jan 12;11:608196. doi: 10.3389/fgene.2020.608196. PMID: 33510771; PMCID: PMC7835937.
8. Anthony Honigman/ DermNet Editor in Chief: Adjunct A/Prof Amanda Oakley, Dermatologist, Hamilton, New Zealand. Copy edited by Gus Mitchell/Maria McGivern. February 2018.
9. Vijayakumari M, Reddy DK, Routhu M, Vuchuru M, Reddy NS. Prenatal diagnosis of harlequin ichthyosis: a case report. *Obstet Gynecol Sci*. 2020 Jan;63(1):94-97. doi: 10.5468/ogs.2020.63.1.94. Epub 2019 Dec 9. PMID: 31970133; PMCID: PMC6962590.
10. Richard G. Autosomal Recessive Congenital Ichthyosis. 2001 Jan 10 [updated 2023 Apr 20]. In: Adam MP, Feldman J, Mirzaa GM, Pagon RA, Wallace SE, Amemiya A, editors. *GeneReviews*® [Internet]. Seattle (WA): University of Washington, Seattle; 1993–2025. PMID: 20301593.
11. Schmuth M, Martinz V, Janecke AR, Fauth C, Schossig A, Zschocke J, Gruber R. Inherited ichthyoses/generalized Mendelian disorders of cornification. *Eur J Hum Genet*. 2013 Feb;21(2):123-33. doi: 10.1038/ejhg.2012.121. Epub 2012 Jun 27. PMID: 22739337; PMCID: PMC3548255.
12. Cheryl Levin; Dirk M Elston / Harlequin Ichthyosis Differential Diagnoses/ Nov 03, 2025 .