

Classification of Endometriosis: A Systematic Review

ARTICLE INFO

Article Type

Systematic Review

Authors

AboTaleb Saremi^{1*} , MD
Mohammad Reza Nateghi¹ , MD

1- Sarem Gynecology, Obstetrics and Infertility Research Center, Sarem Women's Hospital, Iran University of Medical Sciences (IUMS), Tehran, Iran

2- Sarem Cell Research Center (SCRC), Sarem Women's Hospital, Tehran, Iran

ABSTRACT

Endometriosis is a chronic inflammatory disease in which endometrial-like tissue develops outside the uterus. The present study is a systematic review to classify the types of endometriosis. In this study, 10 classifications of endometriosis were investigated. Even though a considerable period has passed since the identification of endometriosis, a comprehensive and integrated classification has not yet been proposed. We believe that according to the findings related to gene expression, shortly, five disorders of superficial peritoneal endometriosis, cystic ovarian endometriosis (endometrioma), deep endometriosis, extra-pelvic endometriosis, and adenomyosis will be classified as five similar diseases, rather than five forms of a single disease.

Keywords: Endometriosis; Classification; Systematic Review

*Corresponding Author

AboTaleb Saremi; Sarem Fertility & Infertility Research Center (SAFIR), Sarem Women's Hospital, Iran University of Medical Sciences (IUMS), Tehran, Iran.

Address: Sarem Women Hospital, Basij Square, Phase 3, Ekbatan Town, Tehran, Iran. Postal code: 1396956111, Phone: +98 (21) 44670888, Fax: +98 (21) 44670432.

Received: 19 November, 2022

Accepted: 11 December, 2022

e Published: 11 July 2023

Article History

Introduction

Endometriosis is classically defined as a chronic inflammatory disease in which endometrial-like tissue develops outside the uterus. This disease is seen in ten percent of women of reproductive age. More than half of the women who are treated for infertility have endometriosis. Although more than 150 years have passed since Karl von Rokitansky first identified the disease, little progress has been made in the pathophysiology, diagnosis and treatment (1). The disease can appear with various symptoms depending on the affected area. Severe pelvic pain, especially during menstruation, is the most common symptom of endometriosis. Pain during intercourse and urination, irregular vaginal bleeding, nausea, vomiting, and mood disorders are common in these patients. Apart from pain, usually, women experience the tremendous burden due to infertility (2-4). Generally, it is usually necessary to see the endometriosis tissue by a surgeon to diagnose this disease. However, the ESHRE guideline has suggested that using imaging modalities is sufficient to diagnose some types of endometriosis. Microscopic examination is recommended if it is impossible to make a definite diagnosis by seeing the lesion (5, 6). Currently, there is no known way to prevent endometriosis. Increasing women's awareness, along with timely diagnosis and management, may slow or stop the clinical progression of the disease. Surgical treatment is usually performed for patients if the condition accompanies severe symptoms or other complications. Findings in definitive medical treatments of endometriosis are insufficient. However, these drugs can be used to reduce pain and symptoms. Surgical treatments mainly aim to remove endometrial lesions. Nevertheless, in more complicated cases, surgery might lead to the complete removal of the pelvic organs (6, 7). Endometriosis is usually associated with significant complications, and its treatment substantially burdens societies. One of the most critical variables in choosing the proper remedy is accurately determining the type of endometriosis. The present study systematically reviews different kinds and classifications of endometriosis.

Methods

The current study was conducted based on the Preferred Reporting Items for Systematic Reviews and Meta-Analyses (PRISMA) guideline (8)

Search strategy and eligibility criteria:

The search strategy was designed based on the two primary roots of endometriosis and classification. Studies published in English and whose full text is available were included in the analytical analysis. Two

researchers independently conducted a systematic search in PubMed, Scopus, and Web of Science (WoS) from inception until May 2023

Study selection:

The study selection process was carried out in several stages through the EndNote reference management software to manage the obtained articles. First, duplicate reports were identified by software and manually. Then, in the screening stage, the studies' title, abstract and full texts were evaluated based on the eligibility criteria. The selection process was carried out by two reviewers independently.

The process of collecting data and data items:

Two independent researchers completed the data extraction forms, including the author's name, year of publication, and name of the classification system, its description and applications. The researchers solved conflicts through cooperation.

Results

Results of the systematic review:

As a result of this systematic search, 220 articles were extracted from databases. After removing duplicate records with the help of software and manual, 178 articles were screened based on eligibility criteria. Finally, ten records were included in the qualitative analysis after examining the titles, abstracts and full texts. The classification methods of endometriosis were classified based on the location of endometriosis, imaging manifestations, its appearance, size and degree of penetration, and clinical effects. The PRISMA flow diagram is shown in Figure 1

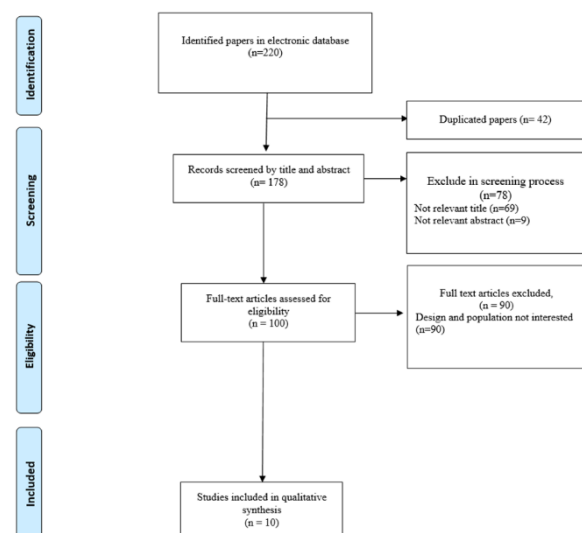



Figure 1. The PRISMA flow diagram of the study

Classification based on appearance and place of conflict:

The World Health Organization has proposed its classification for endometriosis based on the site of involvement. This organization offered four types of superficial peritoneal endometriosis, cystic ovarian endometriosis (endometrioma), deep endometriosis and extrapelvic endometriosis in their classification (9). This classification is very similar to Imperiale et al study classifications. Their study does not consider endometriosis outside the pelvic cavity as one of the main types of endometriosis. It should be noted that the World Health Organization has also considered this type to be very rare (10). Another approach introduced by Nisolle et al. divides endometriosis into three colors, red, black and white, based on the appearance. These colors represent the developmental stages of the disease. Red lesions are the first stage of endometriosis. These vascular lesions are very hyperemic and active. Black lesions represent the second stage and advanced endometriosis. Finally, the red lesions become white. White endometriosis is usually latent and has no specific symptoms (11). The revised American Fertility Society (rAFS) classification is the oldest and most cited classification of endometriosis. This classification focuses on the appearance of the tissue. Figure 2 shows the paper form of this endometriosis classification system (Figure 2). According to this classification, the four stages of endometriosis include minimal, mild, moderate and severe. Being superficial or deep, moderate transparency, the cul-de-sac disappearance, and the lesion's size influence its stage (12). A few years after rAFS was introduced, ENZIAN was added as an auxiliary component (Figure 3). This classification for endometriosis with deep infiltration uses a compartment part (including the letters ABC) and a numerical factor. The compartment ranges from involvement of the retrovaginal space, termed grade A, to involvement of the rectum, termed grade C. The numerical part is also determined based on the lesion size (13).

 **AMERICAN SOCIETY FOR REPRODUCTIVE MEDICINE**
REVISED CLASSIFICATION OF ENDOMETRIOSIS

Patient's Name _____ Date _____
Stage I (Minimal) - 1-5 _____ Laparoscopy _____ Laparotomy _____ Photography _____
Stage II (Mild) - 6-15 _____ Recommended Treatment _____
Stage III (Moderate) - 16-40 _____
Stage IV (Severe) - >40 _____
Total _____ Prognosis _____

	ENDOMETRIOSIS	Size		
		<1cm	1-5cm	>5cm
PERITONEUM	Superficial	1	2	4
	Deep	2	4	6
	R. Superficial	1	2	4
	L. Superficial	1	2	4
OVARY	Superficial	1	2	4
	Deep	4	16	20
	R. Superficial	1	2	4
	L. Superficial	1	2	4
TUBE	Superficial	1	2	4
	Deep	4	16	20
	R. Superficial	1	2	4
	L. Superficial	1	2	4

POSTERIOR CUL-DE-SAC OBLITERATION

	Partial	Complete
4		40

ADHESIONS

	ADHESIONS	Enclosure			
		<1/3 Enclosure	1/3-2/3 Enclosure	>2/3 Enclosure	
R. Fallopian	Filmy	1	2	4	
	Dense	4	8	16	
	L. Fallopian	Filmy	1	2	4
	Dense	4	8	16	
TUBE	Filmy	1	2	4	
	Dense	4	8	16	
	L. Fallopian	Filmy	1	2	4
	Dense	4	8	16	

*If the fimbriated end of the fallopian tube is completely enclosed, change the point assignment to 16.
Denote appearance of superficial implants types as red (R), red-pink (RP), clear vesicles (C), white (W),
specifications, peritoneal defects, yellow-brown, or black (B) black, hemosiderin deposits, blue). Denote percent of total
described as R____%, W____%, C____%, B____%, and RP____%. Total should equal 100%.

Additional Endometriosis: _____ Associated Pathology: _____

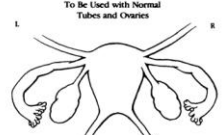

To Be Used with Normal Tubes and Ovaries:  To Be Used with Abnormal Tubes and/or Ovaries: 

Figure 2. Revised Classification of Endometriosis

ENZIAN 2012
Classification of Deep Infiltrating Endometriosis (according to the Endometriosis Research Foundation, SEF)

Compartment
A, B or C

Level


1
< 1 cm

2
1 - 3 cm

3
> 3 cm

F
Uterine and other extragenital deep infiltration endometriosis

FA Adenomyosis
FB Bladder
FU Uterine intramural
FI Intestine, others (Sigmoid, Cecum, Appendix, Ileum)
FO Other localisation (Lung, Diaphragm, Inguinal region, e.g.)



© Koekstein

Figure 3. The ENZIAN Classification of Endometriosis

Classification based on functional disorders caused by endometriosis:

Endometriosis fertility index is also recommended in cases where the patient wants to get pregnant. For pregnancy, the proper functioning of the fallopian tubes, fimbria, and ovaries is required. The surgeon also determines functional scores. They range from 0 to 4 points. If there is severe functional impairment, the patient receives zero points. A score of four means that the patient is normal. Finally, by summing up some other points, such as the points obtained from surgery, a ten-point index is created in which ten means a good prognosis and zero represents the worst prognosis (14). In 2007, the American Association of Gynecological Laparoscopists (AAGL) started a project to create a new classification of endometriosis. Thirty gynecologists were asked to assign points from 0 to 10 for the patients based on the importance of the involvement site. This system contained all the essential information considered important in quantifying a patient's disease extent. In addition, surgical complications were classified into four levels:

- Level 1: removal or drying of surface implants and superficial avascular thin adhesions.
- Level 2: removal of the endometrium of the ovary or appendectomy; Deep endometriosis that does not involve the vagina, bladder, bowel, ureter, or dense adhesions that do not involve the bowel or ureter.
- Level 3, dense adhesions involving the bowel or ureter; Bladder surgery; Ureter or Intestinal surgery without removal (shaving).
- Level 4, bowel resection and anastomosis. Reimplantation of the ureter or its anastomosis.

In 2012, the AAGL collected pain-related visual analogue scale (VAS) scores and history of infertility from patients before surgery to validate their scoring system. However, the AAGL classification has not yet been fully validated and published, although more than ten years have passed since the classification was first proposed. Further investigation and discussion about the AAGL classification are needed (15).

Classification based on imaging:

Ultrasound is one of the most common methods of investigating anatomical issues in women with infertility. Therefore, the researchers introduced the preoperative ultrasound-based endometriosis staging system (UBESS) to estimate the severity of endometriosis before surgery. This method assesses the severity of endometriosis with acceptable accuracy with the help of a transvaginal ultrasound (TVUS) examination. Therefore, the surgeon can estimate the complexity of the operation before performing the surgery. UBESS was added as a backup to some other classification systems (16). One

of the applications of classification based on imaging stereotypes is determining the extent of rectosigmoid involvement in endometriosis. Rectosigmoid involvement is seen in one-third of patients with deep infiltrating endometriosis. Researchers developed the ENDORECT scoring system based on four simple preoperative items. These include palpation of a posterior nodule on digital examination, UBESS score of 3 on TVUS, rectosigmoid infiltration on MRI, and blood in stool during menstruation (17).

Discussion

The present study explains ten different classification methods of endometriosis. These classification methods have tried to categorize situations where the endometrial tissue is located in a place other than its original location. Many studies show that different anatomical types of endometriosis may show distinct gene expressions. In gene expression, information encoded in genes produces functional products such as proteins that perform various biological functions in cells. Depending on changes in gene expression, endometriosis can develop, progress, and respond differently to treatment. Gene expression patterns in different anatomical types of endometriosis have been studied by researchers using various techniques such as microarray analysis and RNA sequencing. Studies have shown potential differences in the gene expression profiles of different forms of the disease, including deep infiltrating endometriosis, ovarian endometriomas (endometriomas), and superficial peritoneal endometriosis. Differentially expressed genes in specific anatomic types of endometriosis may reveal details about the underlying molecular mechanisms and suggest potential therapeutic targets. For example, several genes have been discovered to be dysregulated in endometriotic lesions. These genes are involved in inflammation, hormonal signaling pathways, angiogenesis and tissue regeneration (18). Examining endometriosis gene expression patterns has also helped classify and subtype this disease. Molecular subtypes of endometriosis have been identified through integrative analyzes combining gene expression data with clinical and pathological features. These molecular subtypes may affect prognosis and treatment selection (19). For example, Gueuvoghlian-Silva et al. study showed that GTR, TNFR2, HLA-DR, ICOS CTLA-4, CD45RA, and CD45RO markers are significantly more expressed in regulatory T cells in cases of deep involvement (20). On the other hand, a study demonstrated that FOXO1A, MIG6 and CYP26A1 are more involved in cases where the superficial peritoneum is involved. As a result, each type of endometriosis illustrates very different behaviors. For example, superficial endometriosis usually affects only the surface of the

peritoneum, and simultaneous deep involvement in the bladder or rectum is infrequent in this type. Similarly, in the case of deep involvement, the involvement of the peritoneal surface is not seen simultaneously (21). On the other hand, it seems that although the mentioned categories cover the common types of endometriosis, some types of endometriosis, such as involvement of the uterus and distant areas, which impose a significant burden on patients, have been neglected. Extrapelvic endometriosis refers to the presence of endometrial-like tissue outside the pelvic area. While endometriosis primarily affects pelvic organs such as the ovaries, fallopian tubes, and peritoneum, extrapelvic endometriosis can appear throughout the body. The most common sites involved are the digestive, urinary, and respiratory systems and surgical scars. The exact mechanisms of extrapelvic endometriosis are not fully understood, but several theories have been proposed, including retrograde menstruation, lymphatic or vascular spread, metaplasia, and iatrogenic factors. The clinical manifestations of extrapelvic endometriosis can vary depending on the location of the lesions, including symptoms such as gastrointestinal complaints, urinary dysfunction, breathing problems, and pain. Diagnosis of extrapelvic endometriosis can be challenging and often requires a multidisciplinary approach and integration of clinical evaluation, imaging studies, and histopathological confirmation. Treatment options may include medical management, surgery, or an interdisciplinary approach (22-24). As mentioned, endometriosis is usually a disorder in which tissue similar to the endometrium develops outside the uterus. Adenomyosis is defined as uterine endometrium growth towards the muscular wall of the uterus. Historically, adenomyosis and endometriosis have been considered separate entities. However, recent studies have suggested a possible link between the two conditions (25). It should be noted that in both adenomyosis and endometriosis, the abnormal growth of endometrial tissue is observed outside its usual place. Current literature has stated that both diseases share similar genetic, hormonal, and immunological factors, indicating a common underlying pathogenesis. Endometrial glands and stroma inside the myometrium in adenomyosis further support the notion that adenomyosis is a type of endometriosis (26). It should also be noted that adenomyosis and endometriosis have significant clinical overlap. These two diseases often appear simultaneously in patients. Also, women with adenomyosis often experience pelvic pain, dysmenorrhea, and heavy menstrual bleeding. These symptoms are similar to what is seen in endometriosis. The similarity in clinical manifestations indicates similar pathogenesis between these two conditions (27). Regarding imaging and histological findings, there are significant similarities

between adenomyosis and endometriosis. Imaging methods reveal similarities in the appearance and distribution of lesions in both conditions. This manifestation is consistent with studies that claim that adenomyosis is a type of endometriosis. Histological investigations also show that endometrial glands and stroma are present in a similar way in both adenomyosis and endometriosis (28, 29). Finally, these two disorders have similarities with each other in terms of response to treatment. In other words, adenomyosis responds well to medical and surgical interventions that are usually used for endometriosis. Hormonal therapies, such as gonadotropin-releasing hormone (GnRH) agonists and oral contraceptives, are effective in the management of both adenomyosis and endometriosis mediate. Similarly, surgical methods such as laparoscopy and hysterectomy are used to treat both diseases (30, 31).

Conclusion

Present systematic review evaluated ten articles in the field of endometriosis classification. Despite the fact that a considerable period of time has passed since the identification of endometriosis, a comprehensive and integrated classification has not yet been proposed. We believe that according to the findings related to gene expression, in near future five disorders of superficial peritoneal endometriosis, cystic ovarian endometriosis (endometrioma), deep endometriosis, extra-pelvic endometriosis and adenomyosis will be classified as five similar disease, rather than five forms of a single diseases.

Ethical Issue

There was no ethical issue in this systematic review.

Conflict of interests

There was no conflict of interest in this study.

Source of funding

This study has been financially supported by Sarem Fertility and Infertility Research Center (SAFIR).

Authors' ORCID

AboTaleb Saremi:

<https://orcid.org/0000-0003-4191-6624>

Mohammad Reza Nateghi:

<https://orcid.org/0000-0001-5754-0516>

References

1. Borghese B, Santulli P, Marcellin L, Chapron C. Definition, description, clinicopathological features, pathogenesis and

- natural history of endometriosis: CNGOF-HAS Endometriosis Guidelines. *Gynecologie, Obstetrique, Fertilité & Senologie*. 2018;46(3):156-67.
2. Morotti M, Vincent K, Becker CM. Mechanisms of pain in endometriosis. *European Journal of Obstetrics & Gynecology and Reproductive Biology*. 2017;209:8-13.
 3. Matorras R, Rodríguez F, Pijoan JI, Soto E, Pérez C, Ramón O, et al. Are there any clinical signs and symptoms that are related to endometriosis in infertile women? *American journal of obstetrics and gynecology*. 1996;174(2):620-3.
 4. Martire FG, Lazzeri L, Conway F, Siciliano T, Pietropolli A, Piccione E, et al. Adolescence and endometriosis: symptoms, ultrasound signs and early diagnosis. *Fertility and sterility*. 2020;114(5):1049-57.
 5. Becker CM, Bokor A, Heikinheimo O, Horne A, Jansen F, Kiesel L, et al. ESHRE guideline: endometriosis. *Human reproduction open*. 2022;2022(2):hoac009.
 6. Olive DL, Pritts EA. Treatment of endometriosis. *New England Journal of Medicine*. 2001;345(4):266-75.
 7. Vercellini P, Viganò P, Somigliana E, Fedele L. Endometriosis: pathogenesis and treatment. *Nature Reviews Endocrinology*. 2014;10(5):261-75.
 8. Mardi P, Esmaili M, Irvani P, Abdar ME, Pourrostami K, Qorbani M. Characteristics of children With Kawasaki disease-like signs in COVID-19 pandemic: a systematic review. *Frontiers in pediatrics*. 2021;9:625377.
 9. International Working Group of AAGL E, ESHRE, WES, Tomassetti C, Johnson NP, Petrozza J, Abrao MS, et al. An international terminology for endometriosis, 2021. *Human Reproduction Open*. 2021;2021(4):hoab029.
 10. Imperiale L, Nisolle M, Noël J-C, Fastrez M. Three Types of Endometriosis: Pathogenesis, Diagnosis and Treatment. *State of the Art. Journal of Clinical Medicine*. 2023;12(3):994.
 11. Nisolle M, Donnez J. Peritoneal endometriosis, ovarian endometriosis, and adenomyotic nodules of the rectovaginal septum are three different entities. *Fertility and sterility*. 1997;68(4):585-96.
 12. Rock JA, Group ZES. The revised American Fertility Society classification of endometriosis: reproducibility of scoring. *Fertility and sterility*. 1995;63(5):1108-10.
 13. Haas D, Chvatal R, Habelsberger A, Wurm P, Schimetta W, Oppelt P. Comparison of revised American Fertility Society and ENZIAN staging: a critical evaluation of classifications of endometriosis on the basis of our patient population. *Fertility and sterility*. 2011;95(5):1574-8.
 14. Adamson GD, Pasta DJ. Endometriosis fertility index: the new, validated endometriosis staging system. *Fertility and sterility*. 2010;94(5):1609-15.
 15. Abrao MS, Andres MP, Miller CE, Gingold JA, Rius M, Neto JS, et al. AAGL 2021 endometriosis classification: an anatomy-based surgical complexity score. *Journal of minimally invasive gynecology*. 2021;28(11):1941-50. e1.
 16. Menakaya U, Reid S, Lu C, Bassem G, Infante F, Condous G. Performance of ultrasound-based endometriosis staging system (UBESS) for predicting level of complexity of laparoscopic surgery for endometriosis. *Ultrasound in obstetrics & gynecology*. 2016;48(6):786-95.
 17. Chattot C, Huchon C, Paternostre A, Du Cheyron J, Chouillard E, Fauconnier A. ENDORECT: a preoperative score to accurately predict rectosigmoid involvement in patients with endometriosis. *Human reproduction open*. 2019;2019(2):hoz007.
 18. Izawa M, Taniguchi F, Terakawa N, Harada T. Epigenetic aberration of gene expression in endometriosis. *Frontiers in Bioscience-Elite*. 2013;5(3):900-10.
 19. Eyster KM, Boles AL, Brannian JD, Hansen KA. DNA microarray analysis of gene expression markers of endometriosis. *Fertility and sterility*. 2002;77(1):38-42.
 20. Gueuvoghlian-Silva BY, Bellelis P, Barbeiro DF, Hernandez C, Podgaec S. Treg and NK cells related cytokines are associated with deep rectosigmoid endometriosis and clinical symptoms related to the disease. *Journal of reproductive immunology*. 2018;126:32-8.
 21. Pavone ME, Dyson M, Reirstad S, Pearson E, Ishikawa H, Cheng YH, et al. Endometriosis expresses a molecular pattern consistent with decreased retinoid uptake, metabolism and action. *Human Reproduction*. 2011;26(8):2157-64.
 22. Matalliotakis M, Goulielmos GN, Kalogiannidis I, Koumantakis G, Matalliotakis I, Arici A. Extra pelvic endometriosis: retrospective analysis on 200 cases in two different countries. *European Journal of Obstetrics & Gynecology and Reproductive Biology*. 2017;217:34-7.
 23. Kurushi E, Alimehmeti M, Cekodhima G, Tahiraj M. A case report of extra pelvic multilocular endometriosis. *Int J of Science and Research*. 2017;6:1251-55.
 24. Ortenzi M, Ghiselli R, Trombettoni MMC, Cardinali L, Guerrieri M. Transanal endoscopic microsurgery as optimal option in treatment of rare rectal lesions: a single centre experience. *World*

Journal of Gastrointestinal Endoscopy. 2016;8(17):623.

25. Leyendecker G, Wildt L, Mall G. The pathophysiology of endometriosis and adenomyosis: tissue injury and repair. Archives of gynecology and obstetrics. 2009;280:529-38.
26. Guo S-W. The pathogenesis of adenomyosis vis-à-vis endometriosis. Journal of Clinical Medicine. 2020;9(2):485.
27. Benagiano G, Brosens I, Habiba M. Structural and molecular features of the endomyometrium in endometriosis and adenomyosis. Human reproduction update. 2014;20(3):386-402.
28. Chapron C, Tosti C, Marcellin L, Bourdon M, Lafay-Pillet M-C, Millischer A-E, et al. Relationship between the magnetic resonance imaging appearance of adenomyosis and endometriosis phenotypes. Human reproduction. 2017;32(7):1393-401.
29. Koninckx PR, Martin DC. Deep endometriosis: a consequence of infiltration or retraction or possibly adenomyosis externa? Fertility and sterility. 1992;58(5):924-8.
30. Garcia L, Isaacson K. Adenomyosis: review of the literature. Journal of minimally invasive gynecology. 2011;18(4):428-37.
31. Fedele L, Bianchi S, Frontino G. Hormonal treatments for adenomyosis. Best practice & research Clinical obstetrics & gynaecology. 2008;22(2):333-9.