

## Hemophagocytic Lymphohistiocytosis in an Adult Presenting with Sore Throat and Fever

### ARTICLE INFO

#### Article Type

Case Report

#### Authors

Nilooofar Ghodrati<sup>1</sup>, Bahareh Abbasi<sup>2</sup>,  
Haniye Abbasgholi<sup>2</sup>, Zahra Tavoosi<sup>2</sup>,  
Ata Bushehri<sup>3</sup>, Mohaddese  
Rastgookoorandeh<sup>4\*</sup>

<sup>1</sup> Department of oncology, Shahid Bahonar  
Hospital, Alborz University of Medical  
Sciences, Karaj, Iran

<sup>2</sup> Department of Medical Genetics, National  
Institute of Genetic Engineering and  
Biotechnology, Tehran

<sup>3</sup> Sarem gynecology, Obstetrics and  
Infertility Research Center, Sarem Women's  
Hospital, Iran University of Medical  
Sciences (IUMS), Tehran

<sup>4</sup> Ahram Hospital, Bushehr University of  
Medical Sciences, Bushehr, Iran

#### \*Corresponding Author:

Corresponding author  
Mohaddese Rastgookoorandeh; Ahram  
Hospital, Bushehr University of Medical  
Sciences, Bushehr, Iran  
Email: [mohadesehrastgoo714@gmail.com](mailto:mohadesehrastgoo714@gmail.com)  
Tel: +989120560191

Received: 12 October, 2022  
Accepted: 27 October, 2022  
e Published: 10 April, 2023

#### Article History

Copyright© 2021, ASP Ins. This open-access article is published under the terms of the Creative Commons Attribution-Noncommercial 4.0 International License which permits Share (copy and distribute the material in any medium or format) and Adapt (remix, transform, and build upon the material) under the Attribution-Noncommercial terms.

### ABSTRACT

Hemophagocytic Lymphohistiocytosis (HLH) is a rare but potentially fatal syndrome of immune hyperactivation. The HLH-2004 criteria is a standard guide for the diagnosis of HLH. We report the case of a 48-year-old female who presented with a sore throat, fever, weakness, and lethargy. Initial laboratory tests revealed pancytopenia. A bone marrow aspirate was performed, which revealed hemophagocytosis. The patient fulfilled the HLH-2004 criteria. The present study tries to raise awareness about the proper diagnosis of Epstein-Barr virus (EBV) and to notify clinicians about one of the rarest complications of this disease (HLH).

**Keywords:** Hemophagocytic Lymphohistiocytosis (HLH); Epstein-Barr virus (EBV); Fever; Sore Throat

## لنفوهایستوسیتوز هموفاگوسیتیک در یک بزرگسال با گلودرد و تب

نیلوفر قدرتی<sup>۱</sup>، بهاره عباسی<sup>۲</sup>، هانیه عباسقلی<sup>۳</sup>، زهرا طاووسی<sup>۴</sup>، عطا بوشهری<sup>۲</sup>، محدثه راستگوکورنده<sup>۴\*</sup>

<sup>۱</sup> گروه انکولوژی، بیمارستان شهید باهنر، دانشگاه علوم پزشکی البرز، کرج، ایران

<sup>۲</sup> گروه ژنتیک پزشکی، پژوهشگاه ملی مهندسی ژنتیک و بیوتکنولوژی، تهران، ایران

<sup>۳</sup> مرکز تحقیقات زنان، زایمان و ناباروری صارم، بیمارستان فوق تخصصی صارم، دانشگاه علوم پزشکی ایران، تهران، ایران

<sup>۴</sup> بیمارستان اهرم، دانشگاه علوم پزشکی بوشهر، بوشهر، ایران

### چکیده

لنفوهایستوسیتوز هموفاگوسیتیک (HLH) یک سندرم نادر اما بالقوه کشنده است. معیار HLH-2004 یک راهنمای رایج برای تشخیص HLH است. ما موردی را گزارش کردیم که خانم ۴۸ ساله‌ای با گلودرد، تب، ضعف و بی‌حالی مراجعه کرده است. آزمایشات اولیه پان‌سیتوپنی را نشان داد. آسپیراسیون مغز استخوان انجام شد که هموفاگوسیتوز را نشان داد. بیمار معیارهای HLH-2004 را پر کرد. مطالعه حاضر سعی دارد آگاهی را در مورد تشخیص صحیح EBV افزایش دهد و پزشکان را در مورد یکی از نادرترین عوارض این بیماری (HLH) آگاه نماید.

**کلید واژه‌ها:** لنفوهایستوسیتوز هموفاگوسیتیک (HLH)؛ ویروس اپشتین بار (EBV)؛ تب؛ گلو درد

تاریخ دریافت: ۱۴۰۱/۰۷/۲۰

تاریخ پذیرش: ۱۴۰۱/۰۸/۰۵

\* نویسنده مسئول: محدثه راستگوکورنده

بیمارستان اهرم، دانشگاه علوم پزشکی بوشهر، بوشهر، ایران

تلفن: ۰۰۹۸۹۱۲۰۵۶۰۱۹۱

ایمیل: [mohadesehrastgoo714@gmail.com](mailto:mohadesehrastgoo714@gmail.com)

### Introduction

Fever is a common complaint of outpatients. The numerous differential diagnoses of fever include infections, rheumatological diseases, and malignancies<sup>[1]</sup>. Hemophagocytic lymphohistiocytosis (HLH) is a monoclonal hyperplastic reactive disease of phagocytes that is associated with systemic inflammation. HLH emerges as both primary and secondary cases. The primary type is very rare. It develops with particular mutations in infants younger than two years of age and does not generally have a good prognosis. Secondary HLH usually develops in response to other diseases such as infections, autoimmune diseases, malignancies, weak immunity, and organ transplantation, especially bone marrow. With timely diagnosis and treatment, this disease usually has a good prognosis<sup>[2,3]</sup>. The Epstein–Barr virus (EBV) is one of the most common human viruses worldwide. Most people contract this virus at least once during their lifetime. The symptoms include fatigue, fever, sore throat, hepatosplenomegaly, and skin rashes. A definite diagnosis of active infection is obtained through PCR of the DNA of EBV. Nevertheless, serologic tests can confirm contact with this virus<sup>[4,5]</sup>. The current study introduces a woman with EBV, which has caused secondary HLH.

### Case presentation

The patient was a 48-year-old female who was referred to a general practitioner (GP) with complaints of sore throat, weakness, lethargy, fever that had begun eight weeks prior, and a dry cough. In the first examination, purulent exudate was observed in the tonsils. Mobile lymphadenopathy with a soft texture and a maximum size of 2 cm was palpated in the neck region. However, no lymphadenopathy was palpated in the groins, maxillary, posterior auricular, or submandibular regions. In the abdominal examination, the spleen was palpated 4 cm below the costal margin, and no hepatomegaly was detected (liver span = 10 cm).

Abdominal sonography revealed no ascites. The spleen size was estimated to be 140 mm, but the liver size was normal. No space-occupying lesions were observed in the spleen. The size and tissue of the kidneys were reported as normal. A chest x-

ray of the patient revealed no space-occupying mass or evidence suggesting pleural effusion, fibrosis, or metastasis.

Because tests revealed pancytopenia (Table 1), the patient was referred to an oncologist for PBS and bone marrow aspiration. The results indicated that the bone marrow was hypercellular, and increased lymphocyte ratio, reduced granulocytes, and erythrocytes, and diminished karyocytes count were observed. The number of macrophages had also increased, and hemophagocytosis was clearly observed (figure 1). Based on these findings and through HLH-2004 diagnostic criteria, a definite diagnosis of HLH was made<sup>[6]</sup>. To examine the comorbidity of EBV with this disease, the serology test and EBV DNA PCR were performed, both of which were positive. The patient did not mention any familial history of HLH or X-linked lymphoproliferative disease (XLP).

In addition to supportive treatments such as protection against infection and bleeding, the patient underwent chemotherapy with an eight-week regimen of dexamethasone, etoposide, and cyclosporine as well as intrathecal injection of methotrexate and hydrocortisone (HLH-2004). At the time of diagnosis, the search for an HSCT donor was initiated; however, transplantation was not performed given the patient's proper response to chemotherapy. After improvement, the patient was referred monthly during the first year and annually thereafter for routine examinations. Fortunately, no evidence suggestive of relapse was seen in any of the visits. Three years later, the patient is currently alive and in good condition.

### Discussion

HLH is a hyperactivity syndrome out of the control of the immune system and causes increased inflammation and tissue damage. This disease can develop either as a primary (familial) or a secondary (acquired) case. The primary type occurs due to genetic mutations affecting the cytotoxic properties of lymphocyte T and natural killer cells. The pathogenesis of secondary HLH is not known. What has been proven so far is the role of dysregulation of CD8+ T lymphocytes and non-malignant proliferation of macrophages, causing hypercytokinemia, which leads to the migration of inflammatory cells, infiltration of organs, necrosis, and multi-organ failure<sup>[7,8]</sup>.

Although the incidence of HLH has not been well estimated in the adult population, it is estimated

that this disease has a prevalence of 1.2 cases in every one million people [9]. Common manifestations of HLH in addition to long-lasting fever include hepatosplenomegaly, liver damage, jaundice, hemophagocytosis, and CNS involvement.

Acquired HLH is usually associated with viral infections such as EBV, CMV, and herpes, the most common of which is EBV. EBV can activate familial types of the disease and XLP. Early diagnosis and treatment can enhance the chance of survival of patients with EBV-HLH [10]. The diagnosis of HLH is usually made based on HLH-2004 diagnostic criteria [6]. The patient examined in this study fulfilled six out of eight criteria (Table 1). What made the diagnosis possible in this case was insisting on performing the PBS test in the presence of a known cause for pancytopenia.

Diagnosis of EBV is challenging, given its common manifestations, such as sore throat. The present study aims to raise awareness about the proper diagnosis of EBV and to notify clinicians about one of the rarest complications of this disease (HLH).

#### Competing interests

The authors declare that they have no competing interest regarding the publication of this paper.

#### Acknowledgment

We thank the patient for permitting us to use the medical information for this publication.

#### Funding

This research received no specific grant from any funding agency, commercial, or not-for-profit sectors.

#### Authors' contributions

PM: participated in managing patient and preparing the manuscript. NQ: participated in managing the patient and revised the manuscript critically. AK & SM: substantially drafted the manuscript. All authors read and approved the final version of the manuscript.

#### Abbreviations

HLH: Hemophagocytic Lymphohistiocytosis; EBV: The Epstein–Barr virus; PCR: Polymerase Chain Reaction; CNS: Central Nervous System; XLP: X-Linked Lymphoproliferative Disease

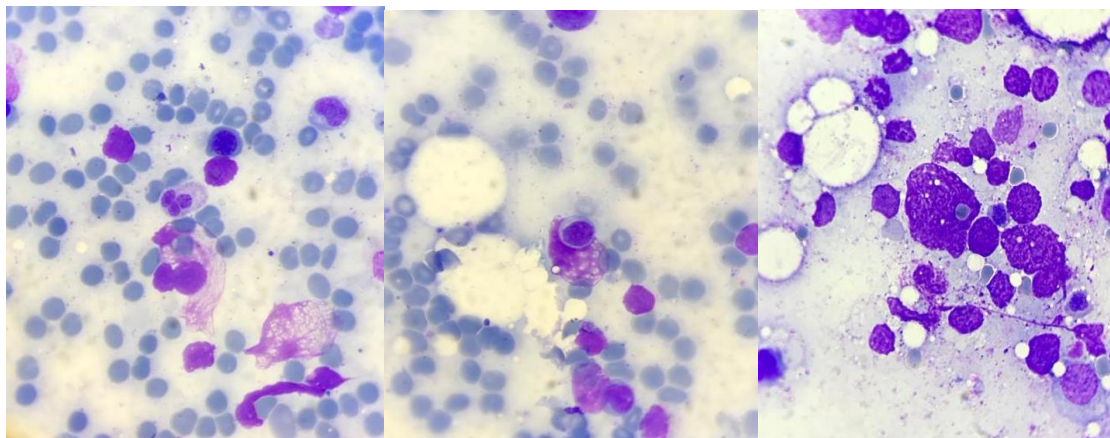
#### References

1. Popovska-Jovičić B, Čanović P, Gajović O, Raković I, Mijailović Ž. Fever of unknown origin: Most frequent causes in adults patients. *Vojnosanitetski pregled*. 2016;73(1):21-5.
2. Al-Samkari H, Berliner N. Hemophagocytic lymphohistiocytosis. *Annual Review of Pathology: Mechanisms of Disease*. 2018;13:27-49.
3. Lehmborg K. Hemophagocytic Lymphohistiocytosis in the Context of Hematological Malignancies and Solid Tumors. *Cytokine Storm Syndrome*: Springer; 2019. p. 437-49.
4. Marsh RA. Epstein–Barr virus and hemophagocytic lymphohistiocytosis. *Frontiers in immunology*. 2018;8:1902.
5. Sullivan JL. Clinical manifestations and treatment of Epstein-Barr virus infection. <http://www.uptodate.com/contents/clinical-manifestations-and-treatment-of-epstein-barr-virus-infection>. 2016.
6. Ramos-Casals M, Brito-Zerón P, López-Guillermo A, Khamashta MA, Bosch X. Adult haemophagocytic syndrome. *The Lancet*. 2014;383(9927):1503-16.
7. Morimoto A, Nakazawa Y, Ishii E. Hemophagocytic lymphohistiocytosis: pathogenesis, diagnosis, and management. *Pediatrics International*. 2016;58(9):817-25.
8. de Saint Basile G, Moshous D, Fischer A. Genetics and Pathogenesis of Hemophagocytic Lymphohistiocytosis. *Histiocytic Disorders*: Springer; 2018. p. 197-214.
9. Niece JA, Rogers ZR, Ahmad N, Langevin AM, McClain KL. Hemophagocytic lymphohistiocytosis in Texas: observations on ethnicity and race. *Pediatric blood & cancer*. 2010;54(3):424-8.
10. Weitzman S. Approach to hemophagocytic syndromes. *Hematology 2010, the American Society of Hematology Education Program Book*. 2011;2011(1):178-83.

**Table1.** Histiocyte Society HLH-2004 diagnostic criteria compared to the described case.

Marker	HLH-2004	Case
Fever (°C)	38.5 or more	38.9
Splenomegaly	Present	Present
Cytopenias (Affecting at least 2 of 3 cell lineages in the peripheral blood.)		
Hemoglobin (mg /L)	< 90	97
Platelets (/L)	< $100 \times 10^9$	$73 \times 10^9$
Neutrophils (/L)	< $1.0 \times 10^9$	$0.54 \times 10^9$
Hypertriglyceridemia and/or hypofibrinogenemia		
Fasting triglycerides (mg/dL)	$\geq 265$	312
Fibrinogen (g/L)	$\leq 1.5$	2.37
Hemophagocytosis in bone marrow or spleen or lymph nodes or liver	Present	Present
Low or absent natural killer-cell activity	Present	Not measured
Ferritin (mg/L)	$\geq 500$	1045
Soluble CD25 (U/mL)	$\geq 2400$	Not measured

This case fulfilled 6 criteria out of 8 criteria. A score of  $\geq 5$  out of 8 is needed for classification of a patient as having definite HLH.



**Figure1.** Hemophagocytosis in PBS and bone marrow. Phagocytosis of erythrocytes, leukocytes, platelets, and their precursors by histiocytes.